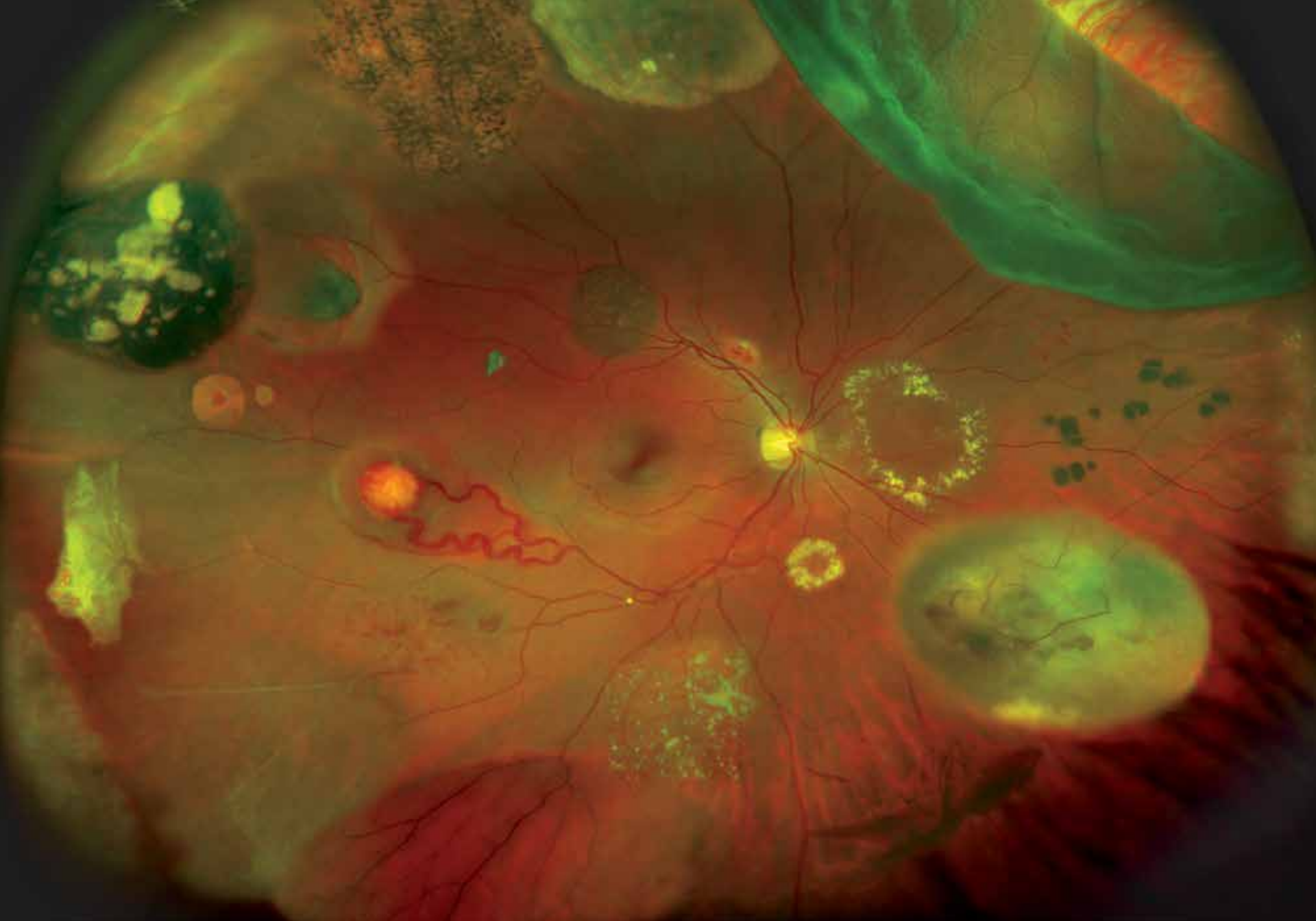



Optos' core devices produce ultra-widefield (UWF™), high resolution digital images (**optomap**®) of approximately 82% and 200° of the retina, something no other device is capable of doing in any single image.

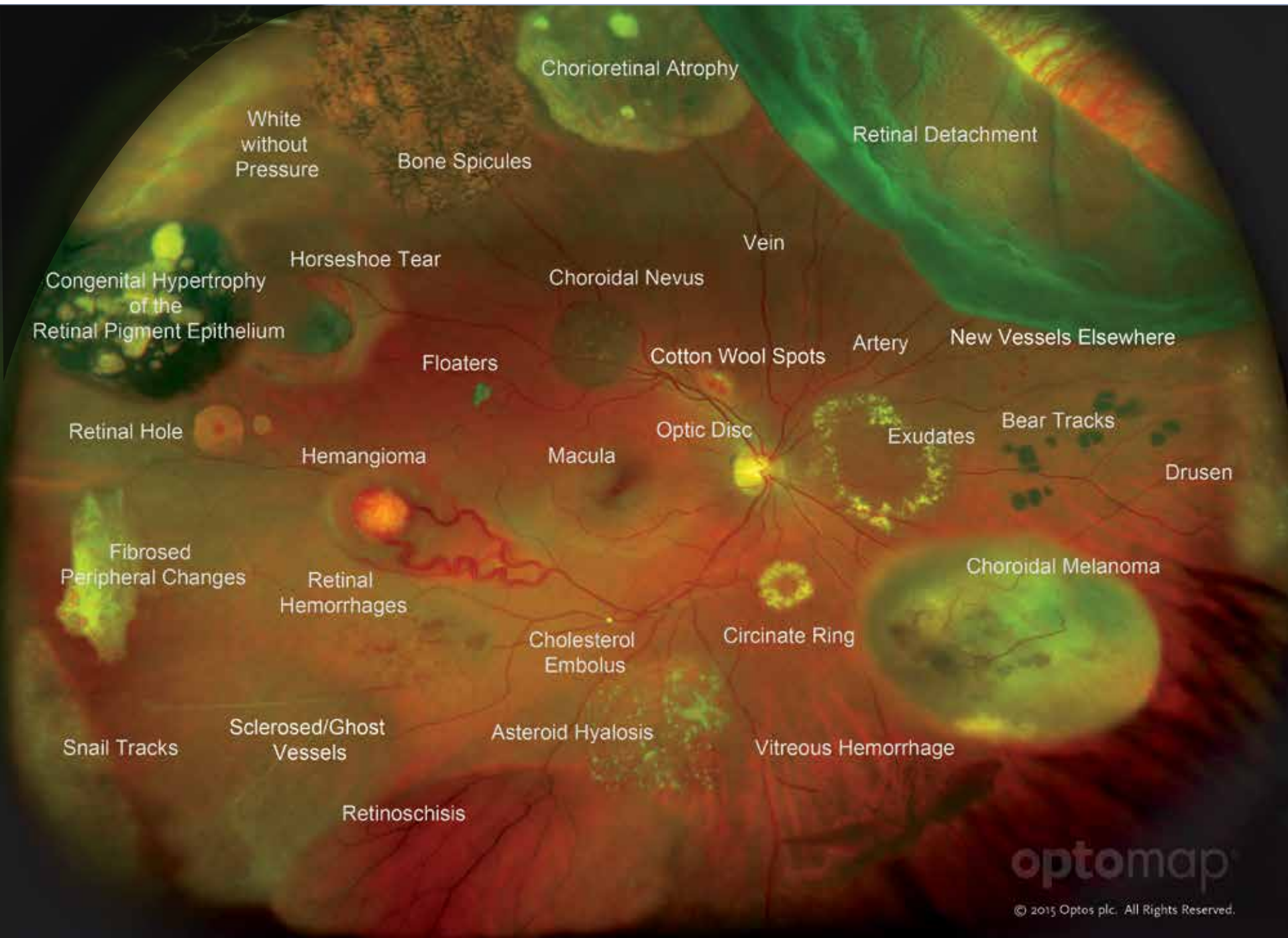
An **optomap** image provides a bigger picture and more clinical information which facilitates the early detection, management and effective treatment of disorders and diseases evidenced in the retina such as retinal detachments and tears, glaucoma, diabetic retinopathy and age-related macular degeneration. Retinal imaging can also indicate evidence of non-eye or systemic diseases such as hypertension and certain cancers.

optomap images consist of two channels of information, a red channel (633nm) which visualizes the choroidal layer and a green channel (532nm) which visualizes the retinal pigment epithelium.

The **optomap** Diagnostic Atlas: *A Retinal Reference Guide* is designed to illustrate how different pathologies are visualized on ultra-widefield images.

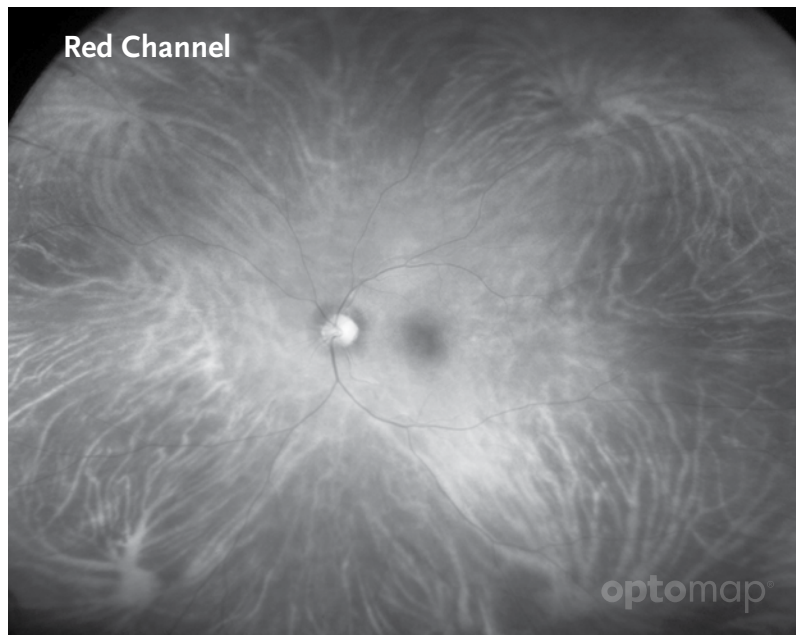
Reference for Definitions

Dictionary of Eye Terminology. Sixth Edition. 2012.
Barbara Cassin and Melvin L. Rubin, MD.
Triad Communications, Inc.

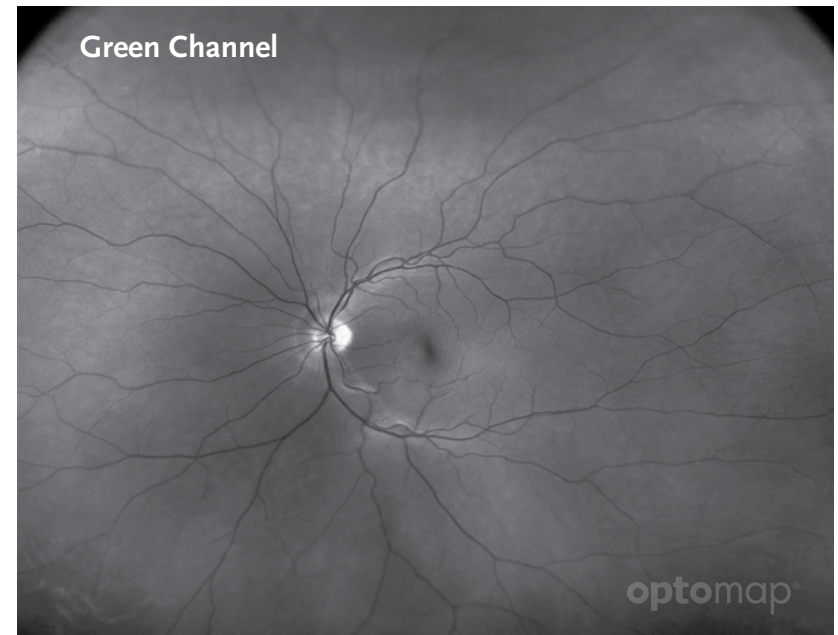


The Retina is the light-sensitive layer of tissue that lines the inside of the eye and sends visual messages through the optic nerve to the brain.

The Choroid is the vascular (major blood vessel) layer of the eye lying between the retina and the sclera. It provides nourishment to outer layers of the retina.



Red channel (633 nm) allows visualization of deeper ocular structures, such as the choroid.



Green channel (532 nm) allows visualization of the sensory retina and pigment epithelium.

Vortex Vein

there are four vortex veins (2 superior, 2 inferior). These veins drain blood from the iris, ciliary body and choroid.

Artery

is a blood vessel that carries blood away from the heart.

Vein

is a blood vessel that carries blood toward the heart.

Retinal Nerve Fiber Layer (RNFL)

the expansion of the fibers of the optic nerve; it is thickest near the nerve diminishing toward the ora serrata.

Macula

is a small central area of the retina surrounding the fovea; area of acute central vision.

Fovea

is the central pit in the macula that produces sharpest vision. Contains a high concentration of cones and no retinal blood vessels.

Optic Disc, Optic Nerve Head (ONH)

is the ocular end of the optic nerve. Denotes the exit of retinal nerve fibers from the eye and entrance of blood vessels to the eye.

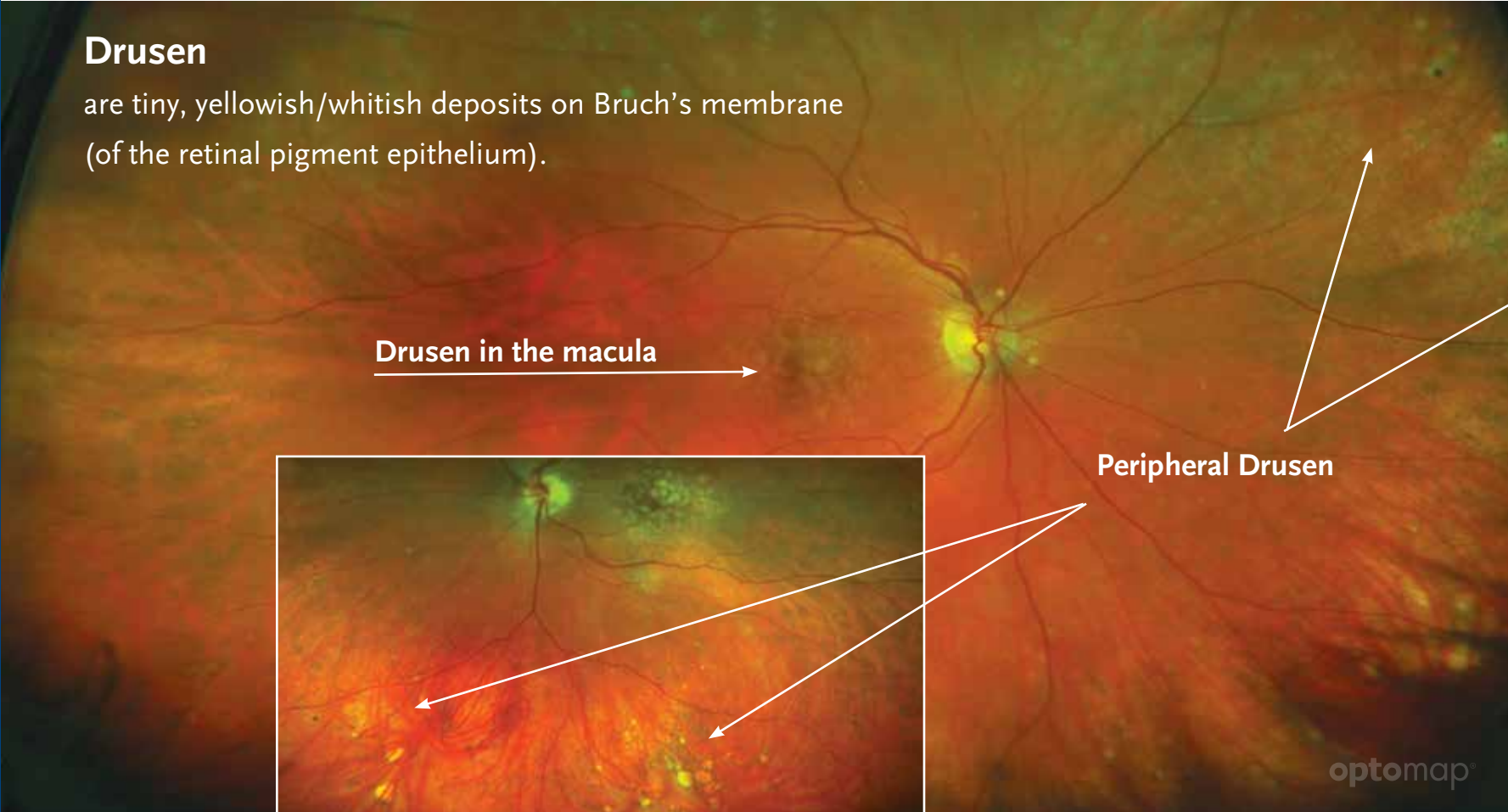
Age-Related Macular Degeneration (AMD, ARMD)

is a group of conditions that include deterioration of the macula, resulting in loss of sharp central vision. Two general types: dry and wet. Dry is usually evident as a disturbance of macular pigmentation and deposits of yellowish material under the pigment epithelial layer in the central retinal zone. Wet is abnormal new blood vessel growth under the retina which leaks fluid and blood, further disturbing macular function. AMD is the most common cause of decreased vision after age 50.

Drusen

are tiny, yellowish/whitish deposits on Bruch's membrane (of the retinal pigment epithelium).

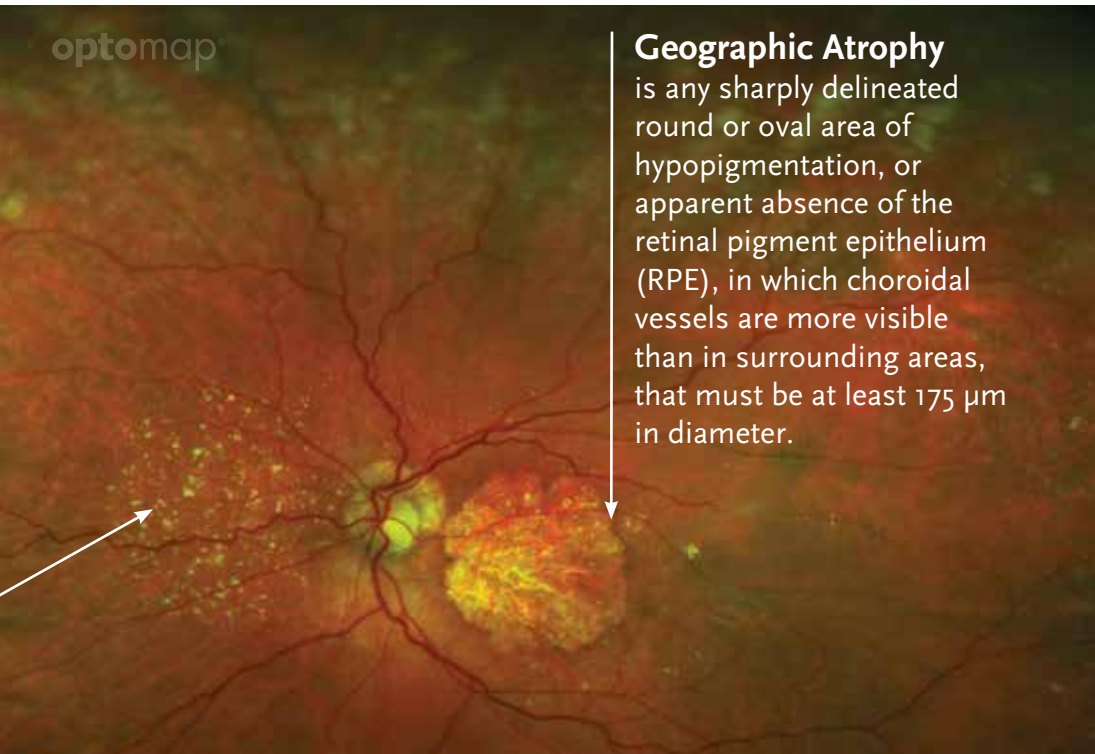
Drusen in the macula



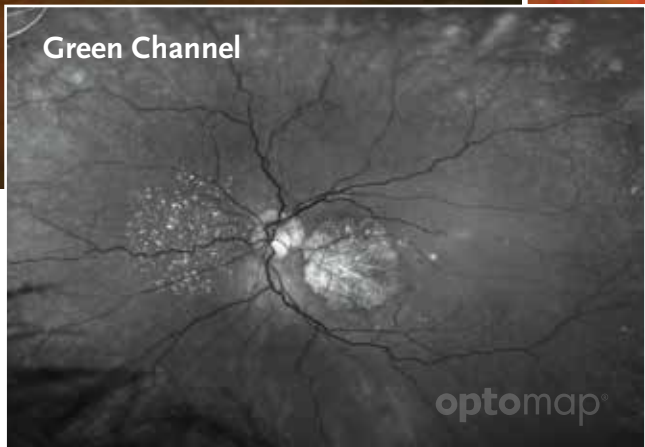
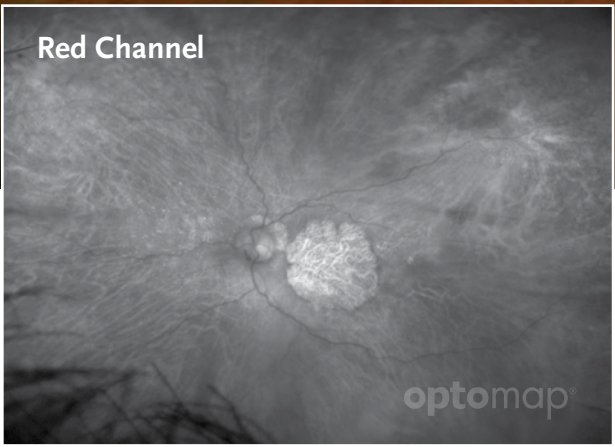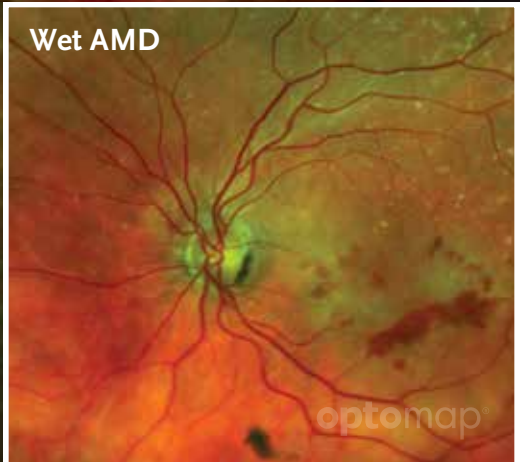
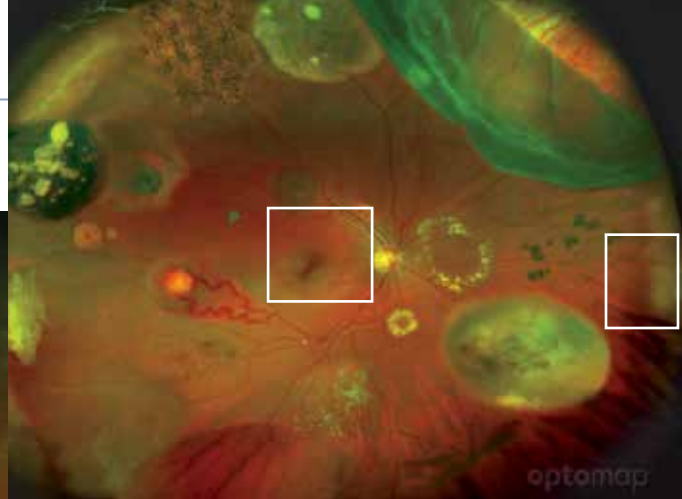
Peripheral Drusen

optomap®

optomap®



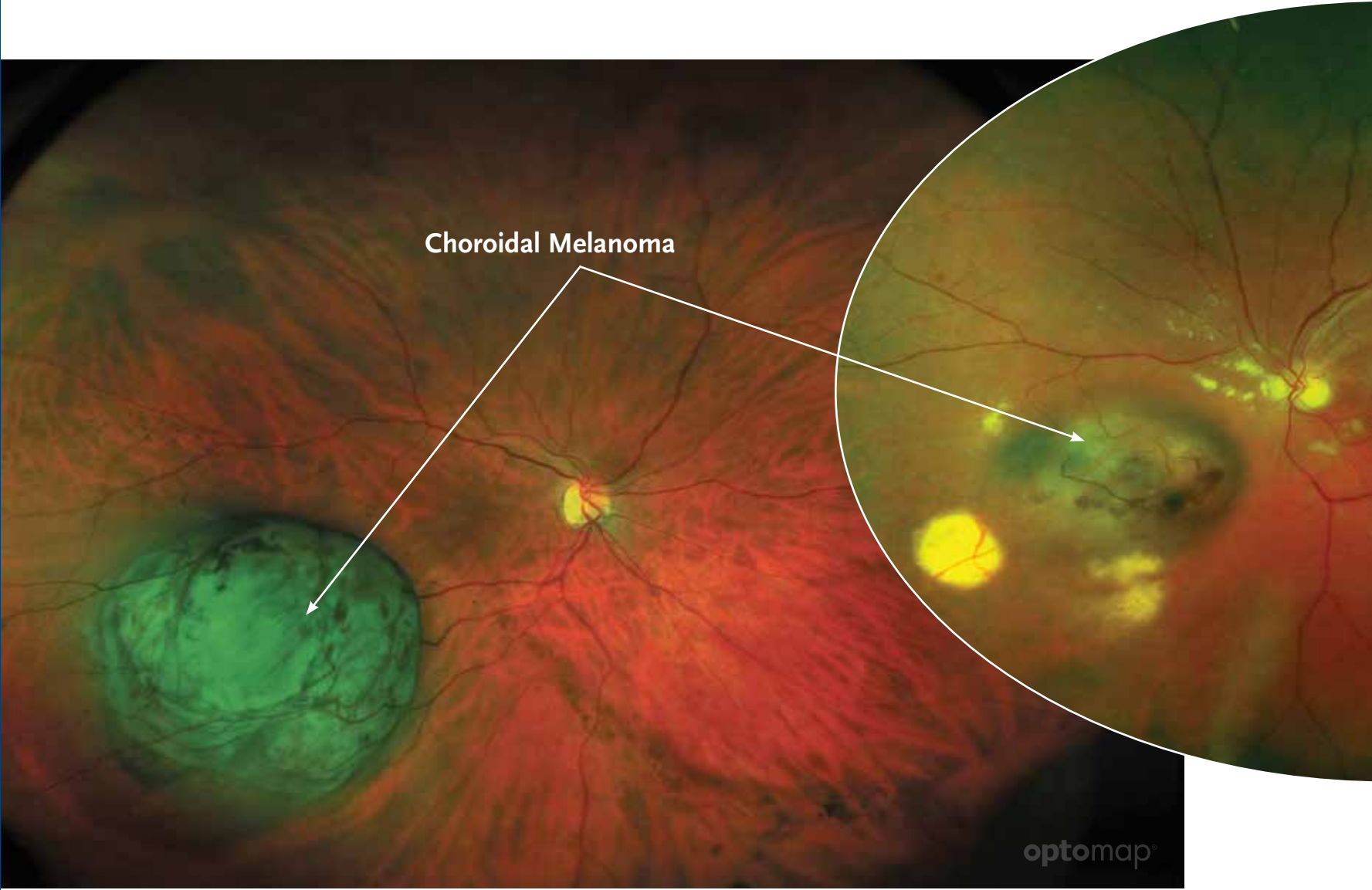
Geographic Atrophy is any sharply delineated round or oval area of hypopigmentation, or apparent absence of the retinal pigment epithelium (RPE), in which choroidal vessels are more visible than in surrounding areas, that must be at least 175 μm in diameter.

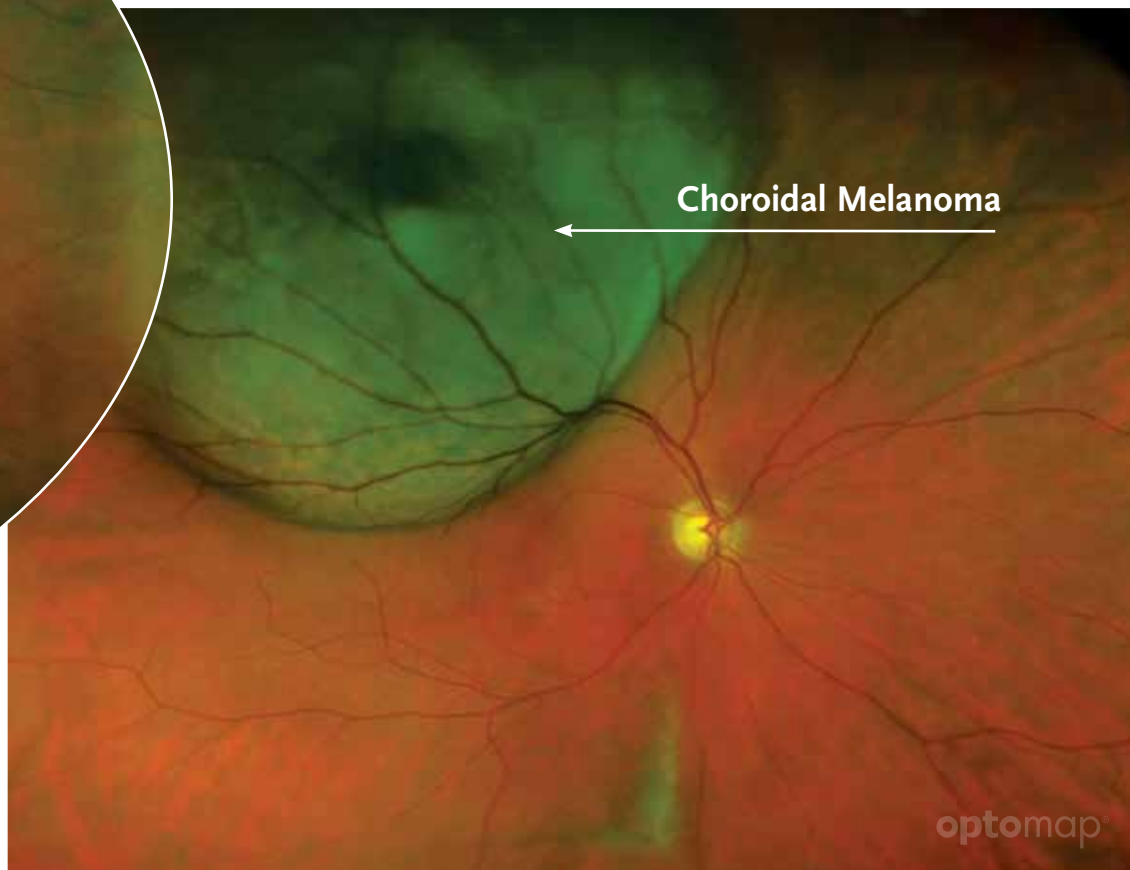
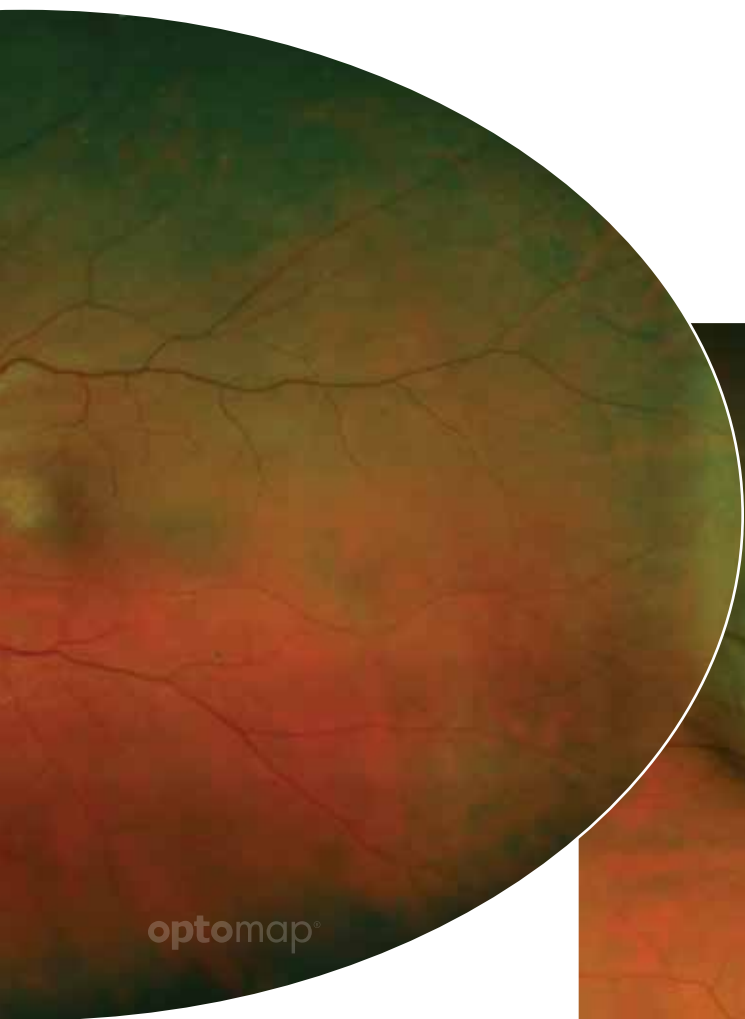
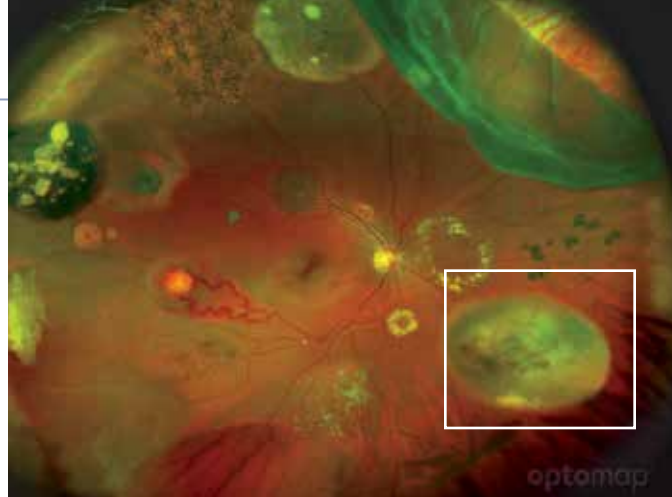


Green channel allows for visualization of drusen whereas they are difficult to distinguish in the red channel.

Choroidal Melanoma

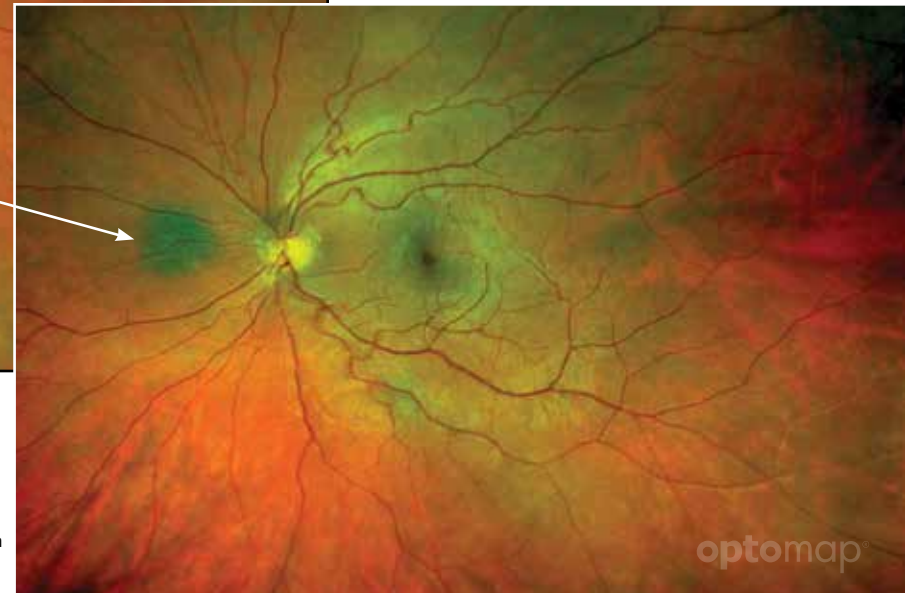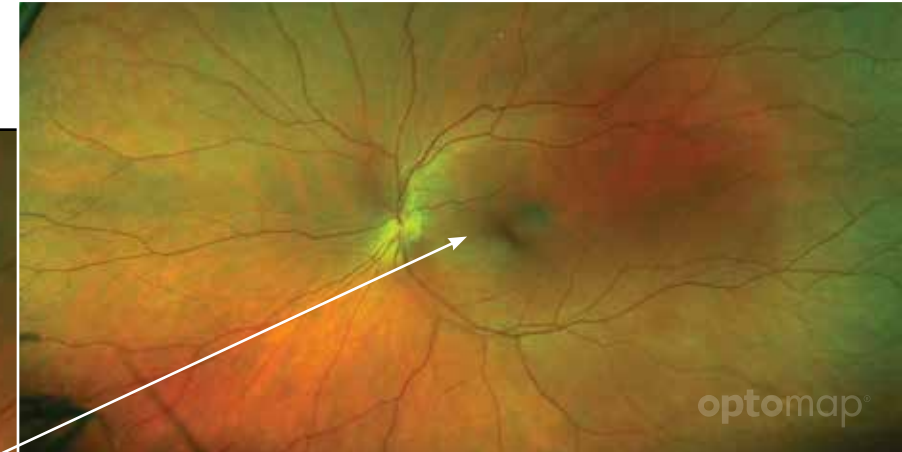
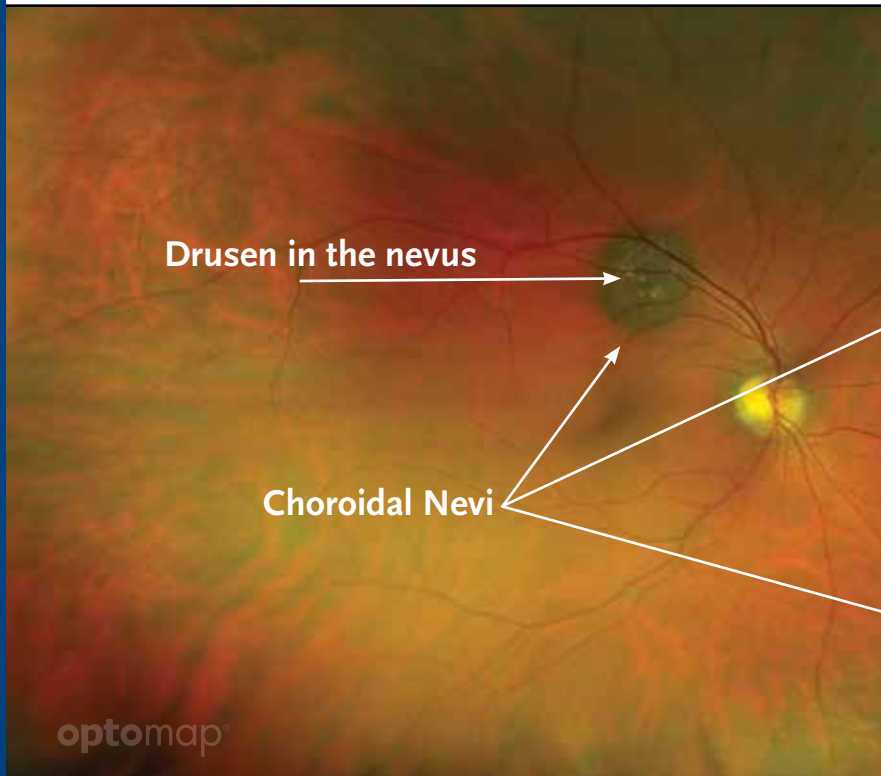
is a malignant tumor derived from pigment cells initiated in the choroid.





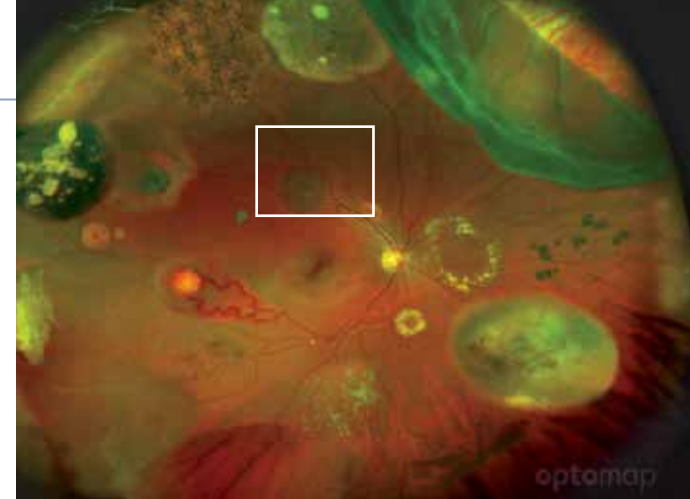
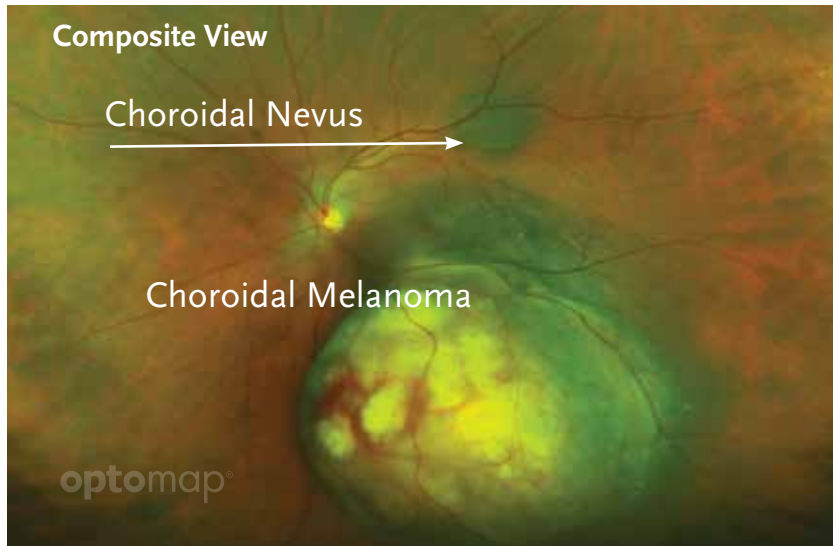
Choroidal Nevi

are a flat, benign pigmented area that appears in the back of the eye. Studies have shown the benefit of imaging choroidal nevi using a widefield scanning laser ophthalmoscope in that the two imaging channels (red 633nm and green 532nm) can be used to help determine the presence of choroidal nevi. Utilizing the ultra-widefield SLO increased the prevalence of visualizing choroidal nevi compared to other population-based studies where an ultra-widefield SLO was not used.¹

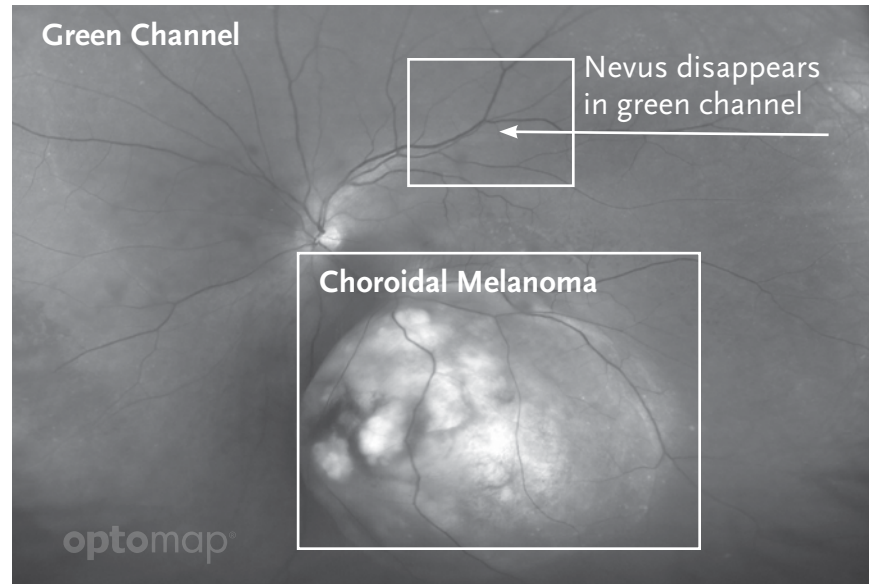
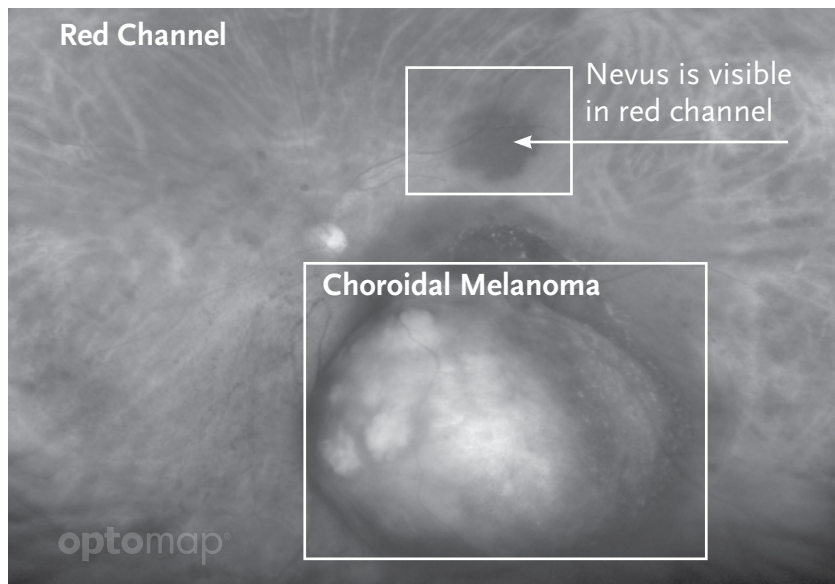


1. Gordon-Shaag A, Barnard S, Millodot M, Gantz L, Chiche G, Vanessa E, Ruth W, Pinchasov R, Gosman Z, Simchi M, Koslowe K & Shneur E. Prevalence of choroidal naevi using scanning laser ophthalmoscope. *Ophthalmic Physiol Opt* 2014, 34, 94–101.

Using different channels to distinguish Choroidal Nevi from Choroidal Melanoma



Choroidal melanoma can be visualized on all channels of an **optomap** image. This is a diagnostic distinction from a choroidal nevus which appears only in the red channel.



Melanoma is visible in both channels


Diabetic Retinopathy

is a series of progressive retinal changes accompanying long-standing diabetes mellitus. Early stage is background retinopathy or non-proliferative diabetic retinopathy (NPDR). It may advance to proliferative retinopathy (PDR), which includes the growth of abnormal new blood vessels (neovascularization) and fibrous tissue.

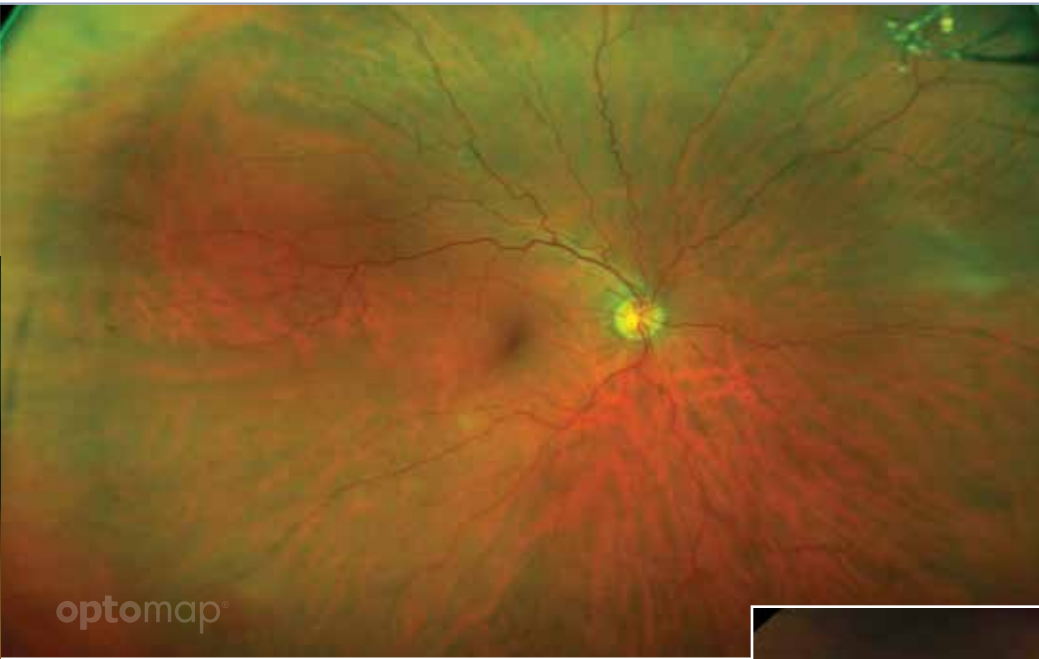
ETDRS 7 Standard Fields Fundus Camera Views

The gold standard for the current detection and classification of diabetic retinopathy is stereoscopic color fundus photographs in 7 standard fields, as defined by the Early Treatment Diabetic Retinopathy Study (ETDRS) group.

Recent research has established the importance of monitoring the retinal periphery (area outside of ETDRS) for the progression of diabetic retinopathy.²

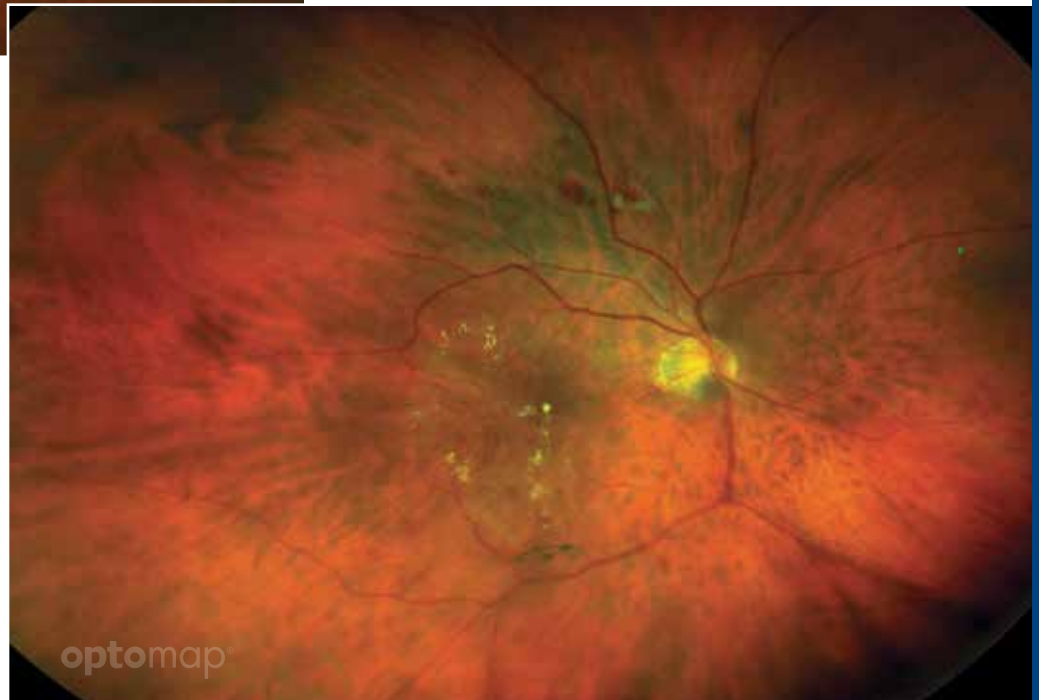

2. Paolo S. Silva, MD, Jerry D. Cavallerano, OD, PhD, Nour Maya N. Haddad, MD, Hanna Kwak, BS, Kelli H. Dyer, DO, Ahmed F. Omar, MD, Hasanain Shikari, MD, Lloyd M. Aiello, MD, Jennifer K. Sun, MD, MPH, Lloyd Paul Aiello, MD, PhD. Peripherhal Lesions Identified on Ultrawide Field Imaging Predict Increased Risk of Diabetic Retinopathy Progression over 4 Years. Ophthalmology. February 2015.



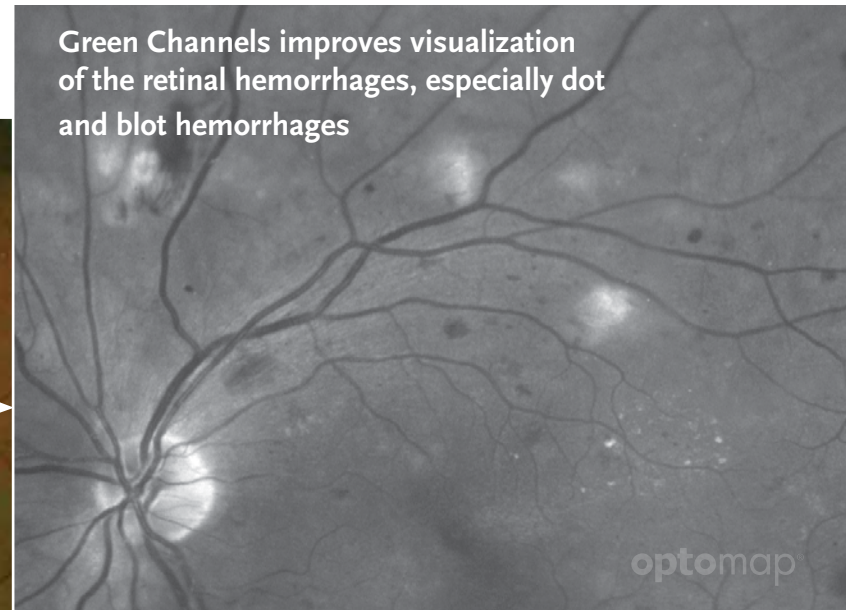
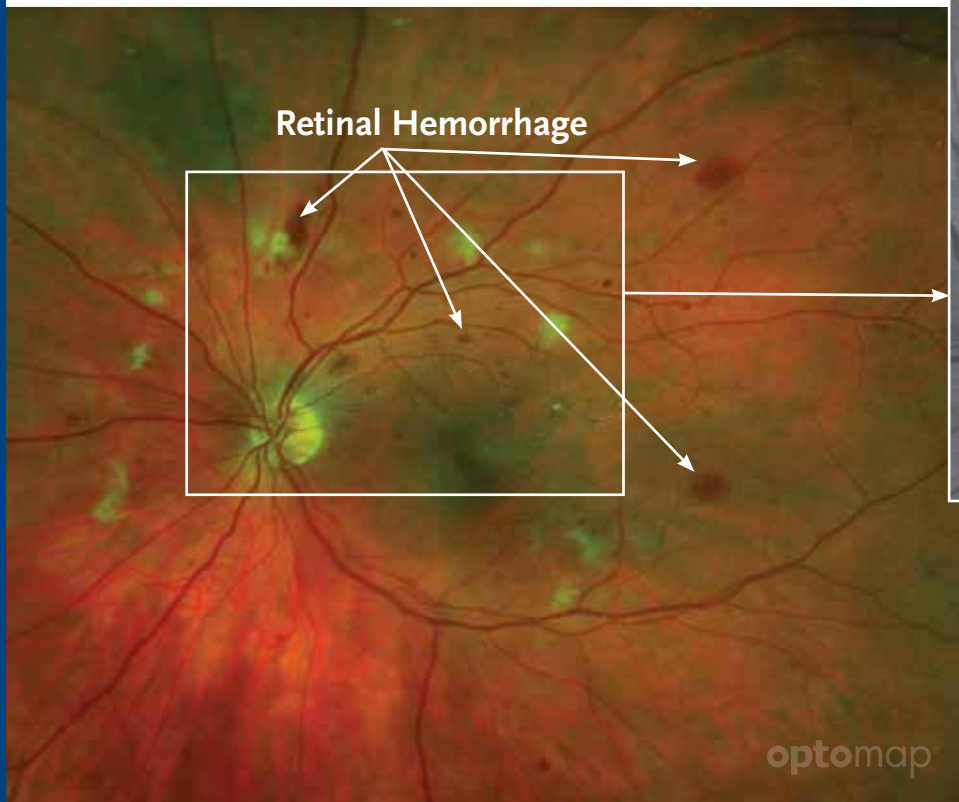
Non-Proliferative Diabetic Retinopathy demonstrating retina hemorrhages in the periphery.

Proliferative Diabetic Retinopathy demonstrating retinal hemorrhages, cotton wool spots, exudates, floaters, diabetic macular edema, microaneurysms and intraretinal microvascular abnormalities.



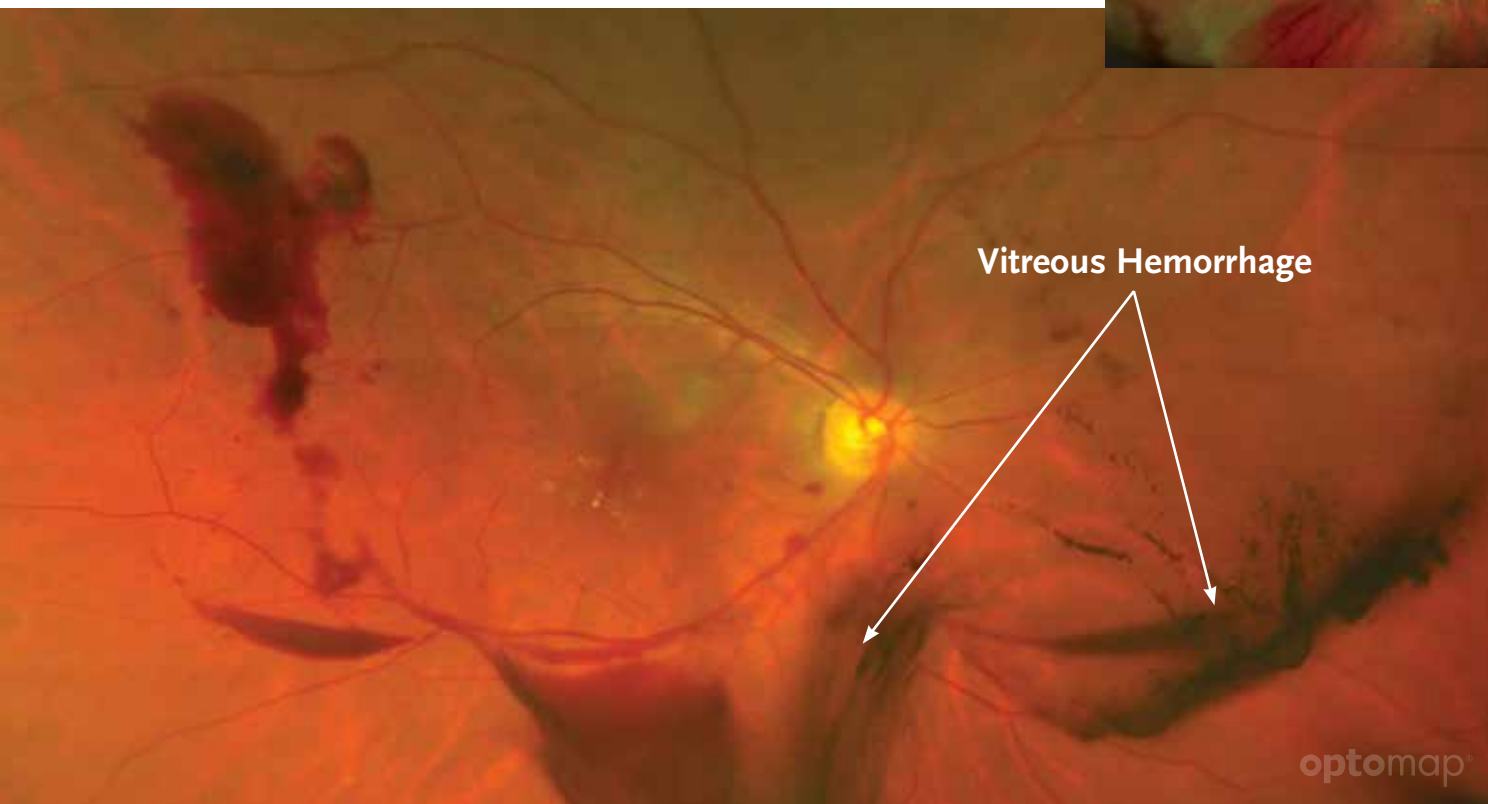
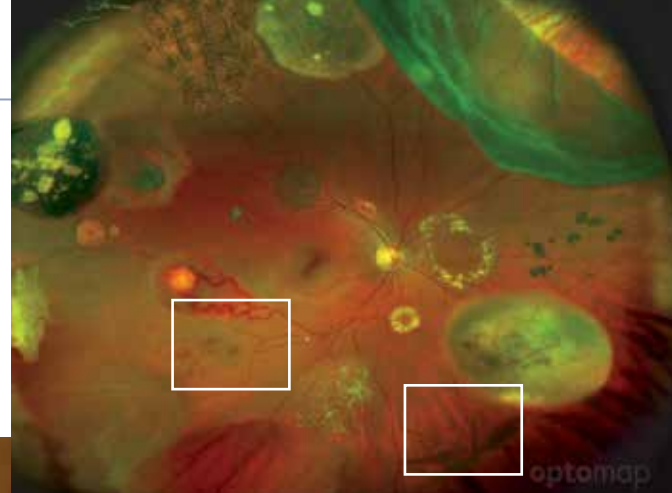
Retinal Hemorrhage

is the abnormal bleeding of the blood vessels in the retina. These blood vessels can become damaged by injury or disease and may bleed, causing temporary or permanent loss of vision. Dot and blot hemorrhages are tiny round hemorrhages in the retina, usually in the outer plexiform layer.



Vitreous Hemorrhage

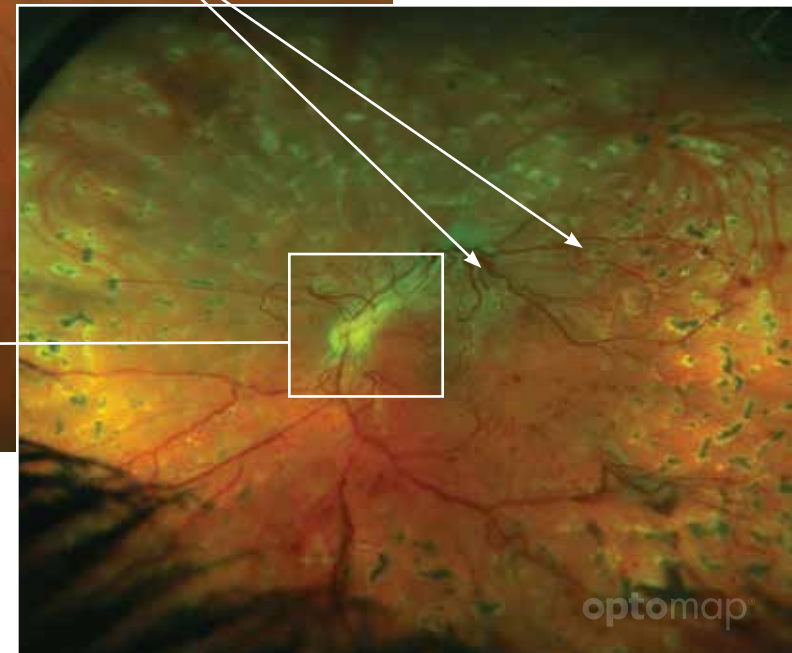
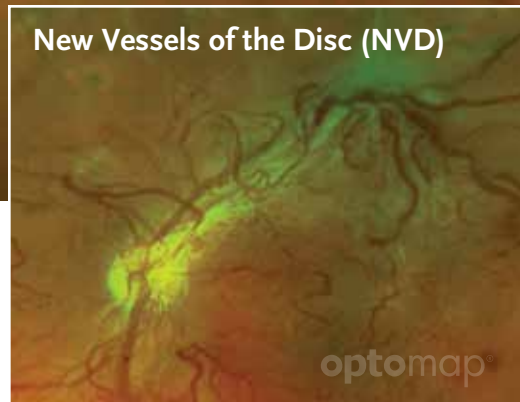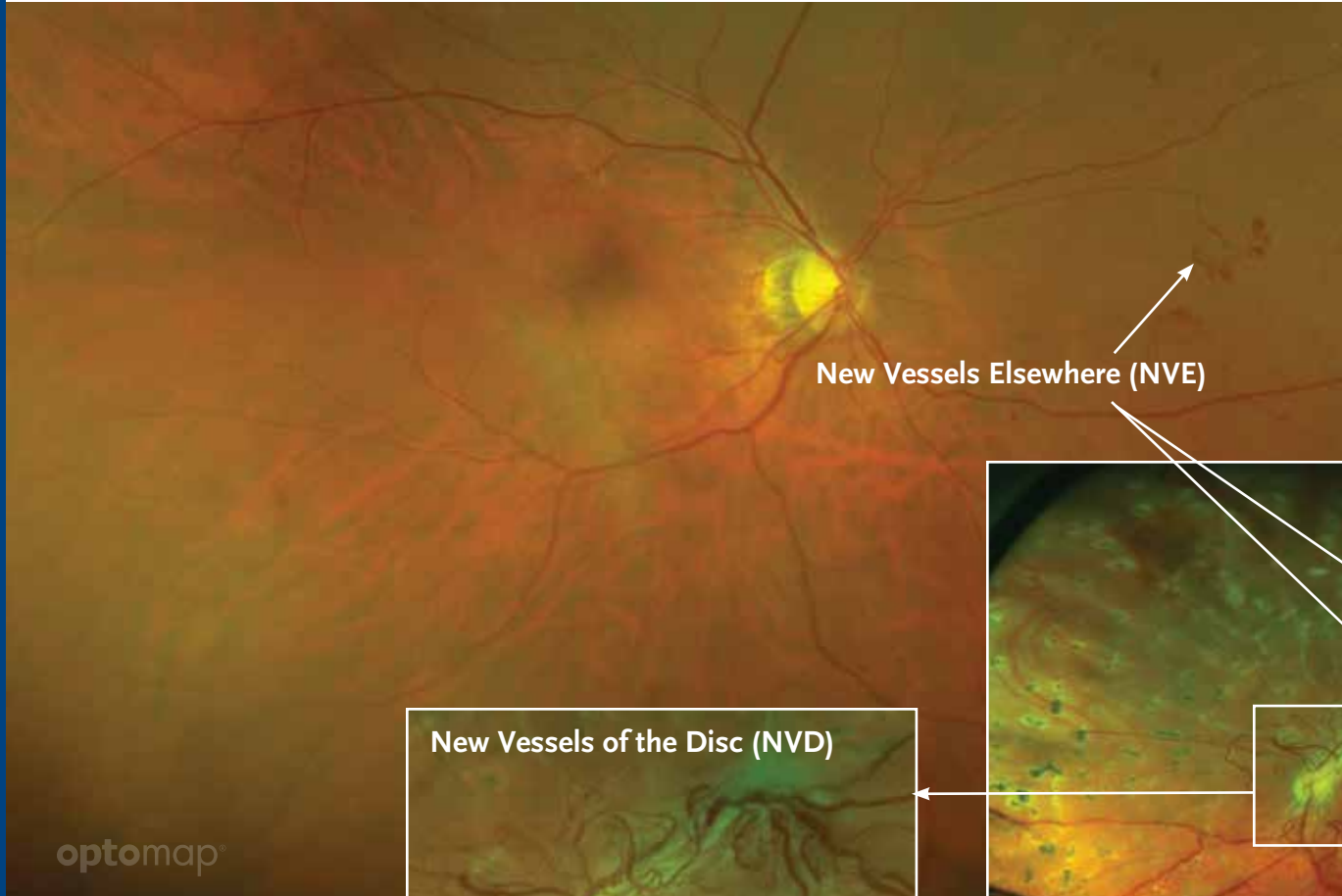
is blood in the vitreous that may result from blunt eye trauma, blood leakage from neovascularization, vitreous detachment or a retinal tear. It is also called a vitreal bleed and typically associated with diabetes.



Vitreous hemorrhages are easily visible on **optomap** due to the SLO system which allows clear visualization of structures in the vitreous, anterior to the retina.

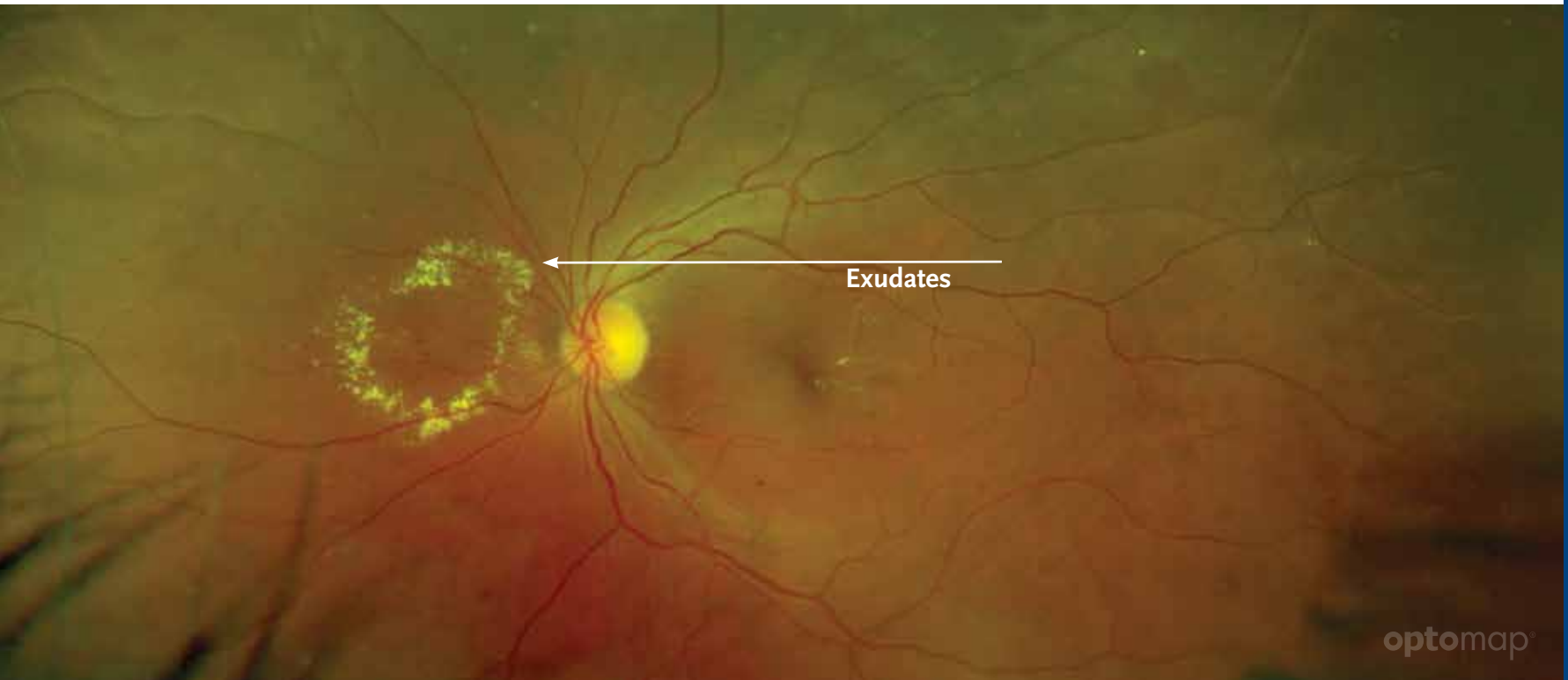
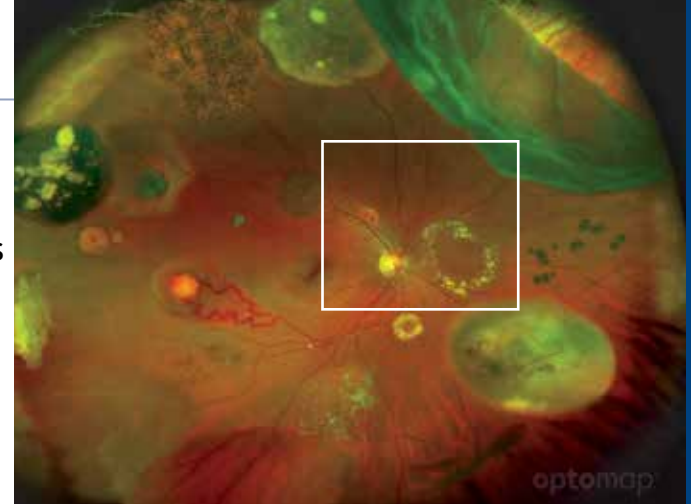
Neovascularization

is the abnormal formation of new blood vessels, usually in or under the retina or on the iris surface. These may develop in diabetic retinopathy, blockage of the central retinal vein, macular degeneration, sickle cell retinopathy, or retinopathy of prematurity.



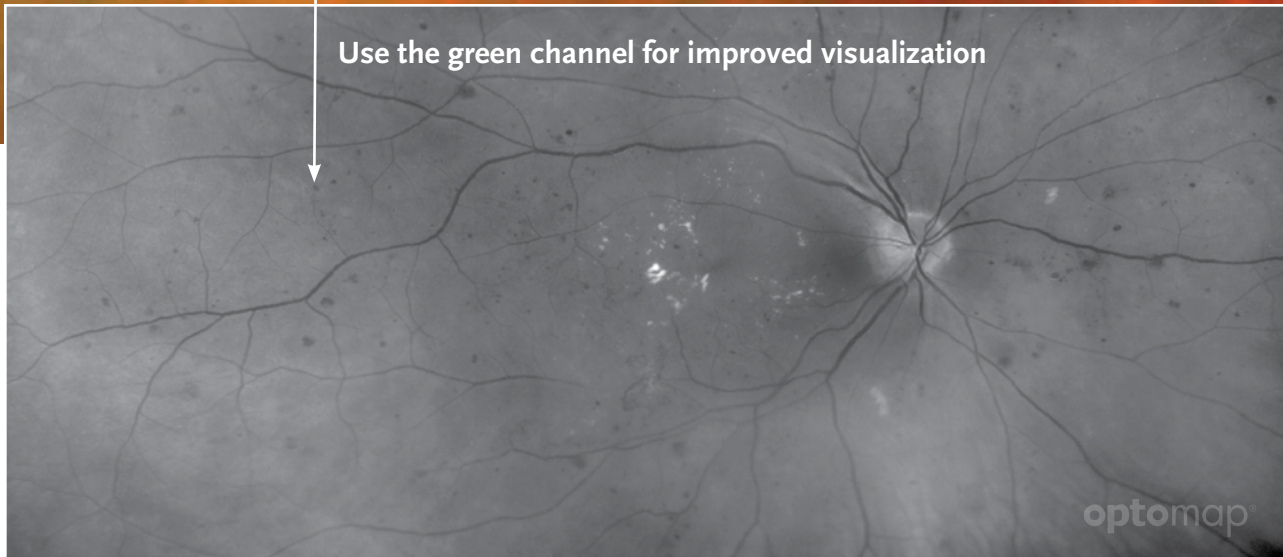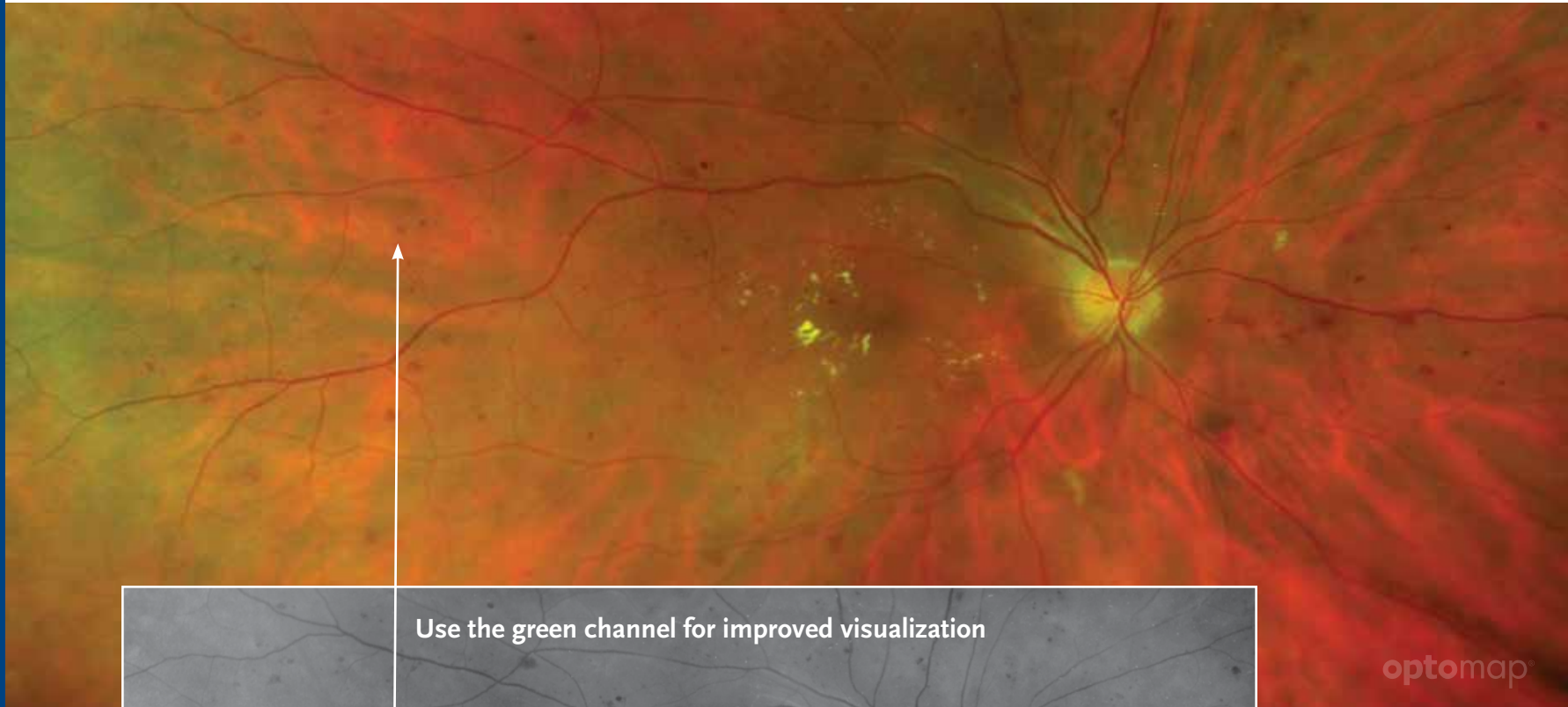Exudates

are proteins or lipid fluid that leaks from blood vessels into the surrounding tissue or space. There are two types of exudates: hard and soft. Soft exudates are “fluffy looking” white deposits within the retinal nerve fiber layer that represent small patches of retina that have lost their blood supply by vessel obstruction (ischemic infarcts). These are not true exudates and are often called cotton wool spots. Hard exudates have less fluid content and higher density of fat and protein.



Microaneurysms

are focal dilation of the venous end of retinal capillaries. These appear in the retinal vessels as a small round red spot resembling a tiny, deep hemorrhage.

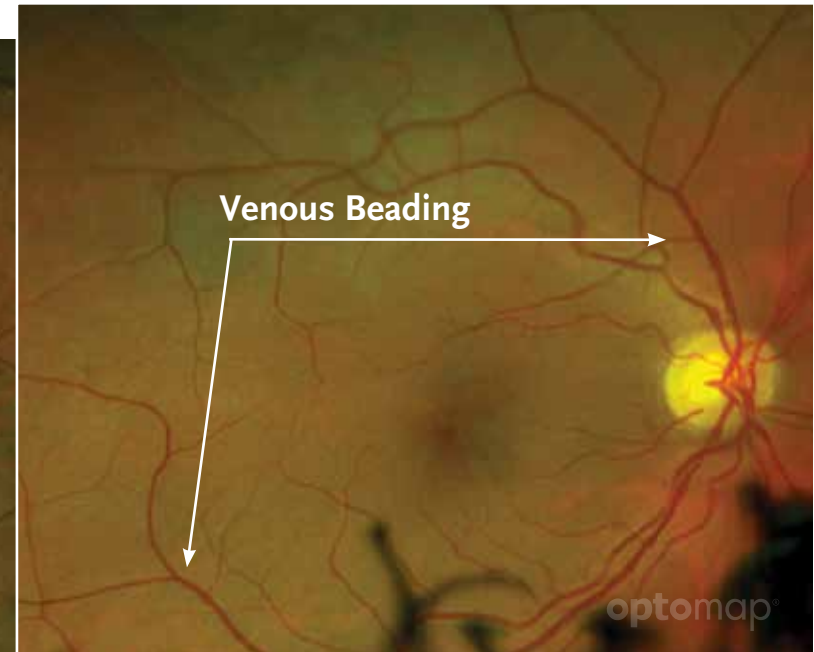
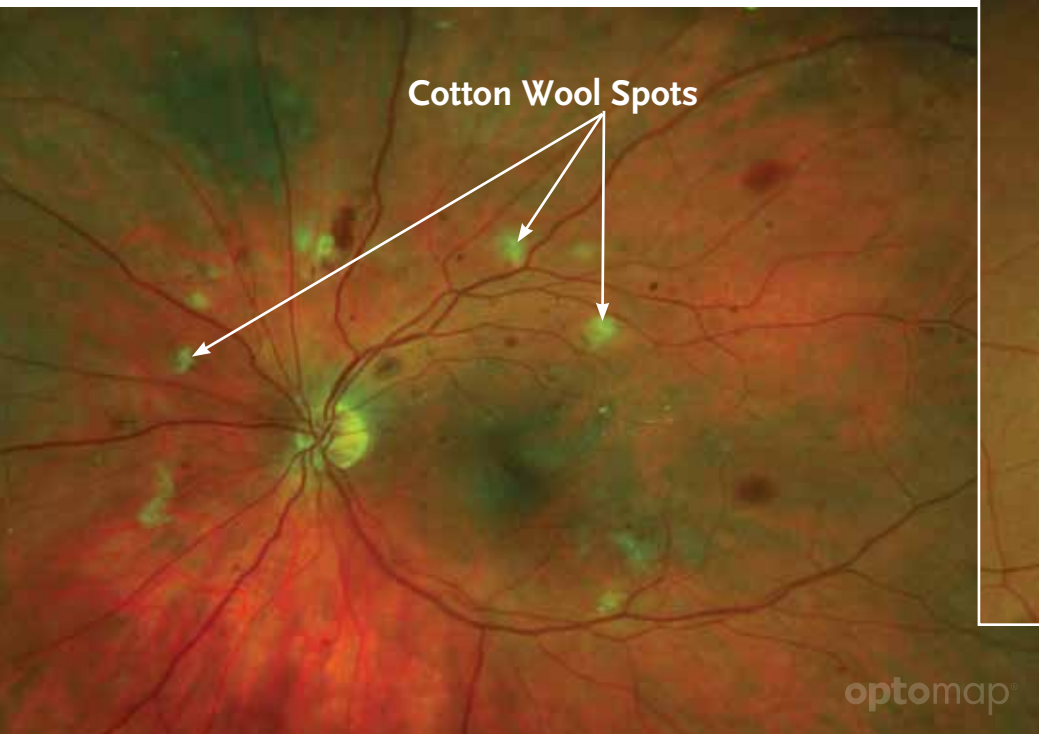
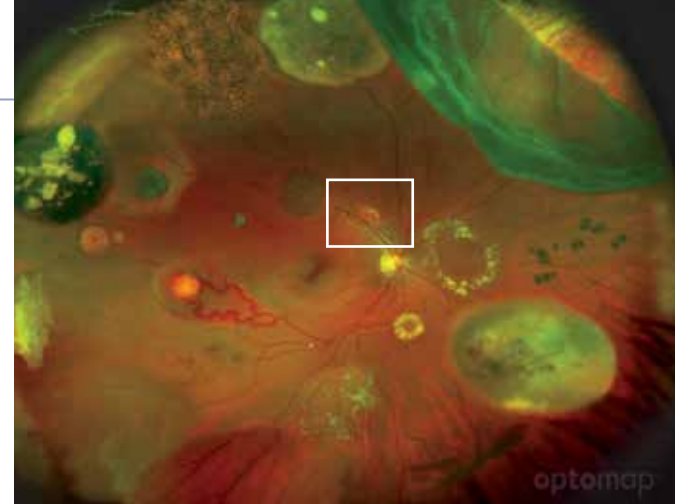


Cotton Wool Spots

are yellow-white deposits within the nerve fiber layer that represent small patches of retina that have lost their blood supply from vessel obstruction. These are associated with hypertensive and diabetic retinopathies.

Venous Beading

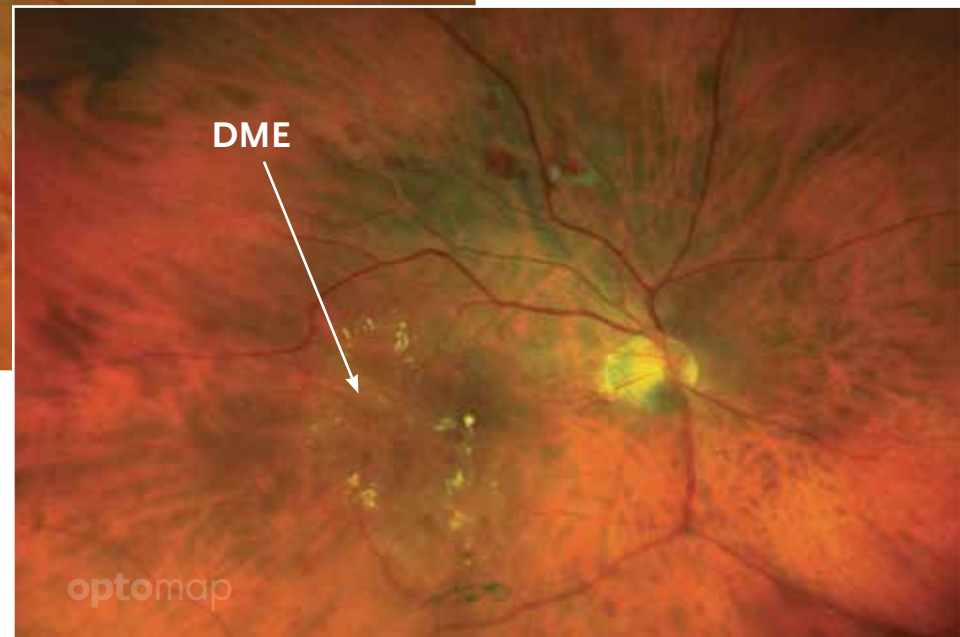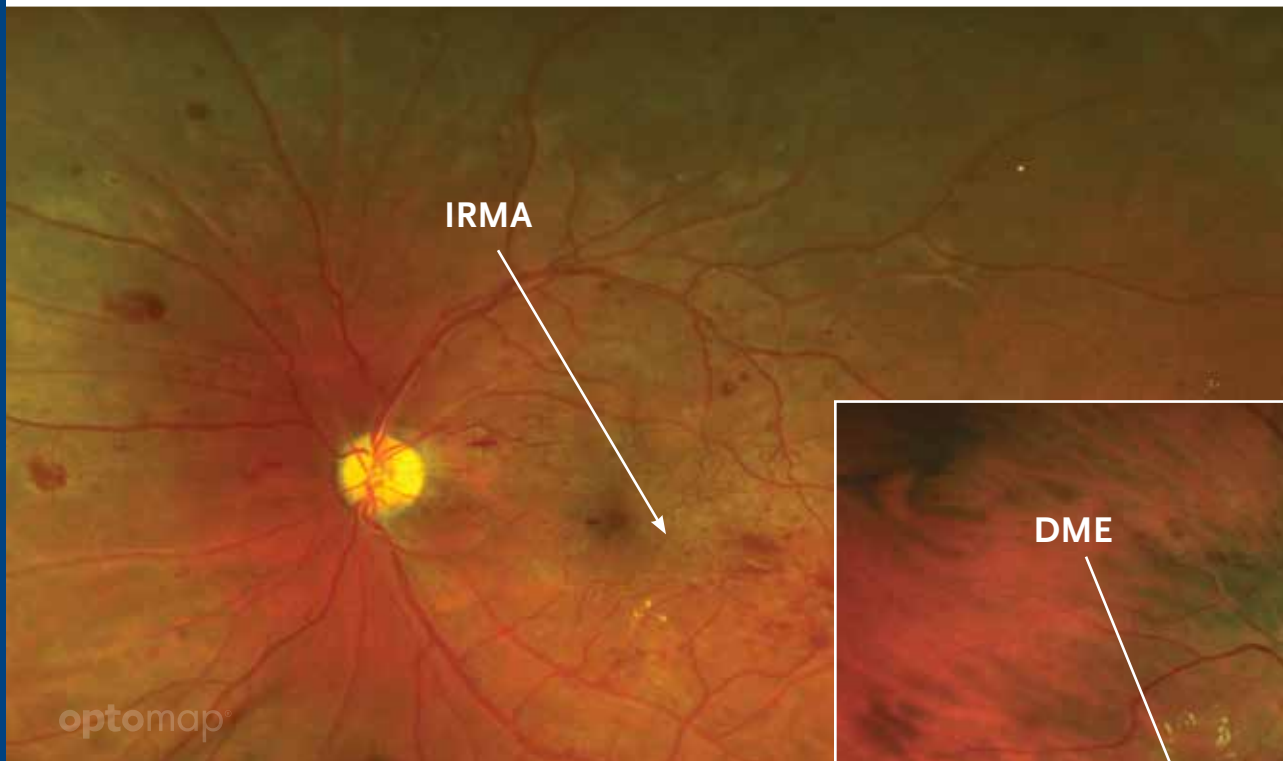
is a pattern of nodular irregularity in the retinal venous blood vessel walls. This can be found in Coats' disease and diabetic retinopathy.



Intraretinal Microvascular Abnormalities (IRMA)

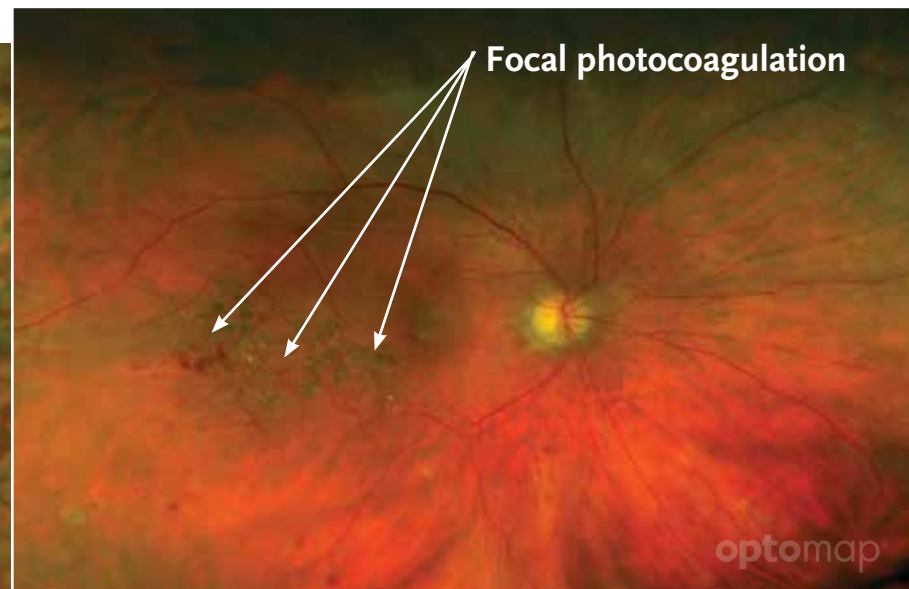
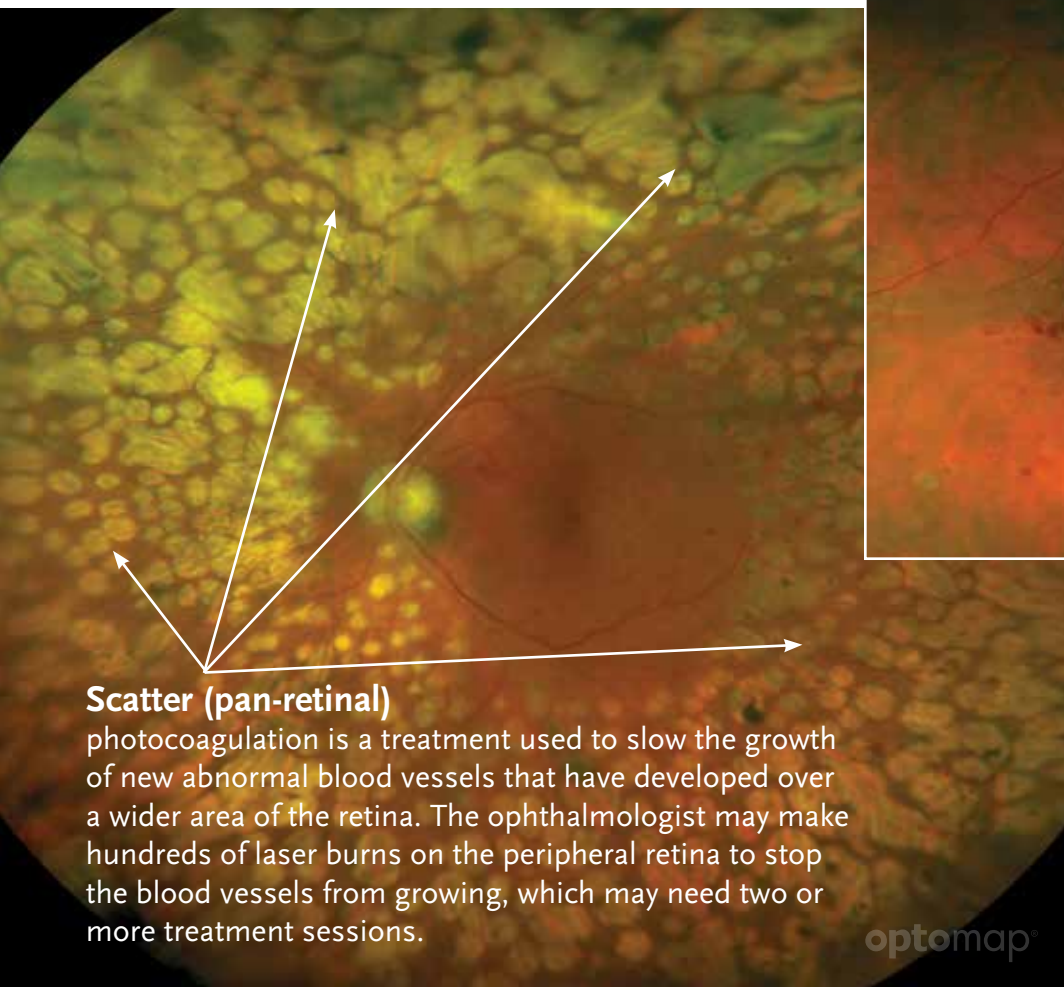
is a development of abnormal blood vessels with tiny aneurysms along with connections (shunts) from arterioles to venules. They occur in hypertensive and diabetic retinopathy, when blood is unable to flow through the normal capillaries, resulting in retinal anoxia and possible retinal swelling (edema).

Diabetic Macular Edema (DME) is retinal swelling and cyst formation in the macula area. It usually results in temporary decrease in vision, though it may become permanent.



Pan Retinal Photocoagulation (PRP)

is used to treat diabetic retinopathy. Laser photocoagulation uses the heat from a laser to seal or destroy abnormal, leaking blood vessels in the retina. Focal and scattered photocoagulation are two types. **optomap** imaging can be used to help determine areas that need laser treatment.



Focal photocoagulation is a treatment used to seal specific leaking blood vessels in a small area of the retina, usually near the macula. The ophthalmologist identifies individual blood vessels for treatment and makes a limited number of laser burns to seal them off.

Retinal Detachment

is the separation of the retina from the underlying pigment epithelium. It disrupts the visual cell structure and thus markedly disturbs vision. It is almost always caused by a retinal tear and often requires immediate surgical repair.

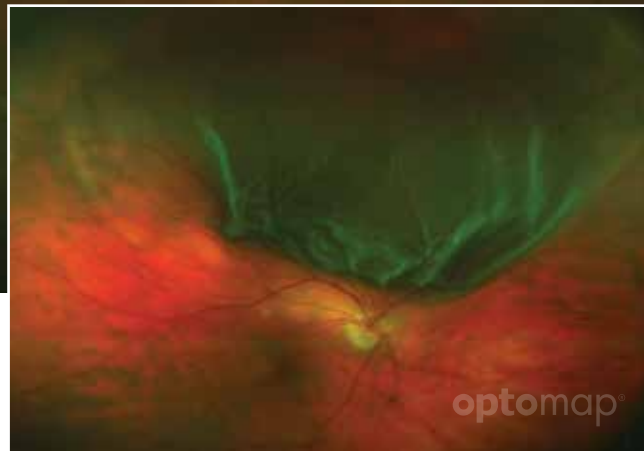Rhegmatogenous—A tear or break in the retina allows fluid to get under the retina and separate it from the retinal pigment epithelium (RPE), the pigmented cell layer that nourishes the retina. These types of retinal detachments are the most common.

Exudative—Frequently caused by retinal diseases, including inflammatory disorders and injury/trauma to the eye. In this type, fluid leaks into the area underneath the retina, but there are no tears or breaks in the retina.

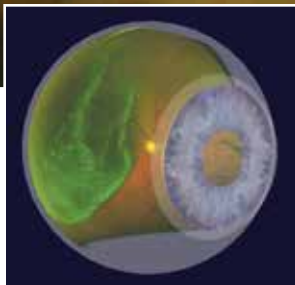
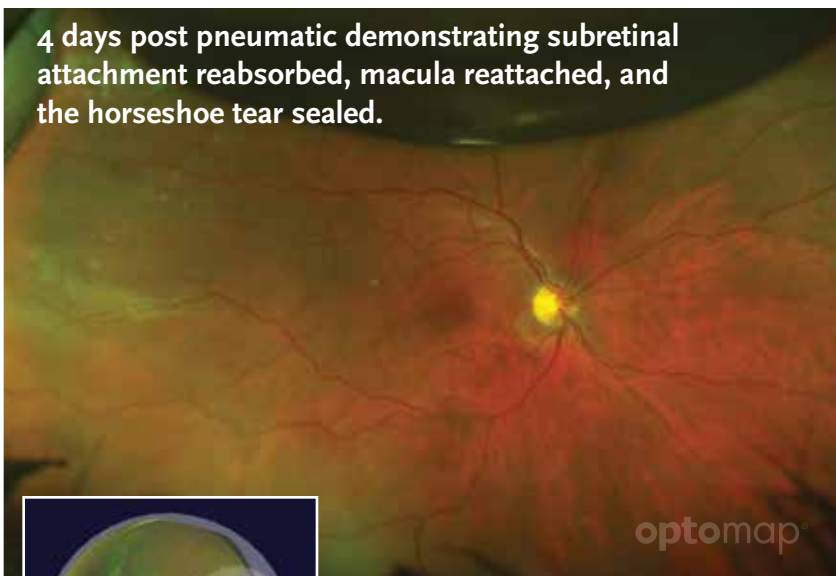
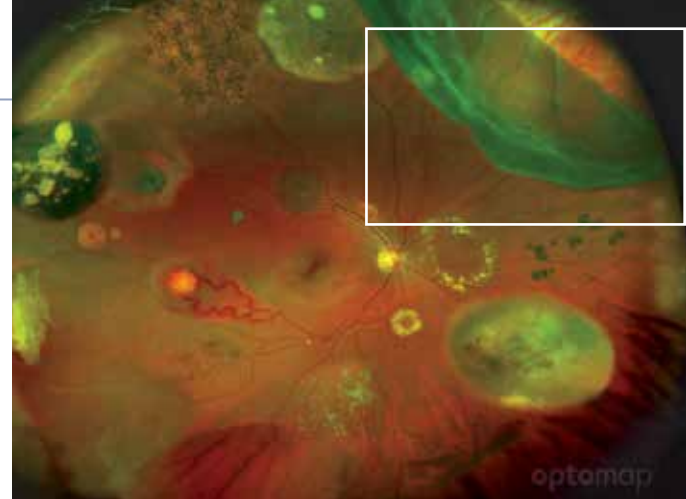
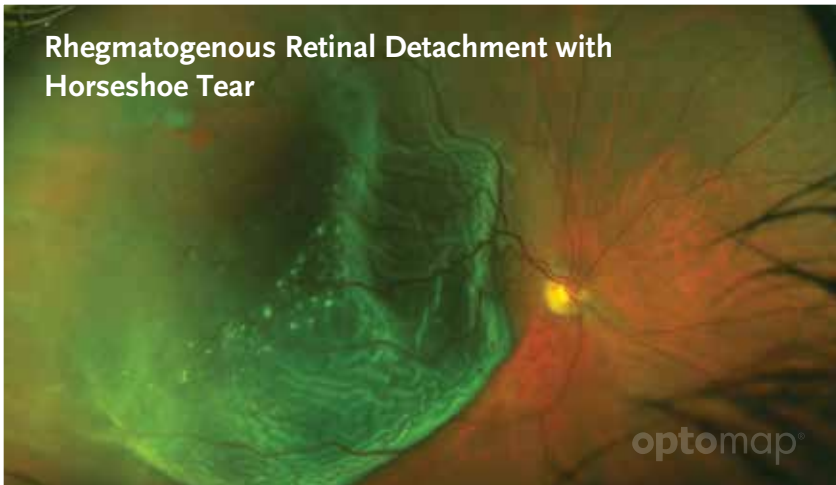Tractional—In this type of detachment, scar tissue on the retinal surface contracts and causes the retina to separate from the RPE. This type of detachment is less common.

Floater

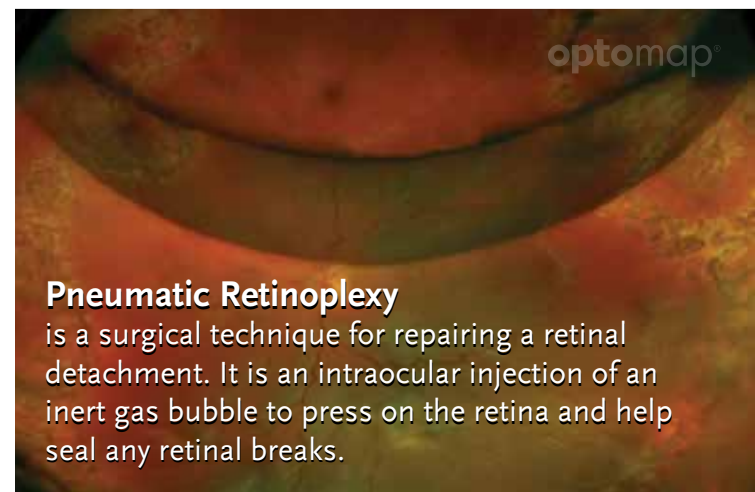
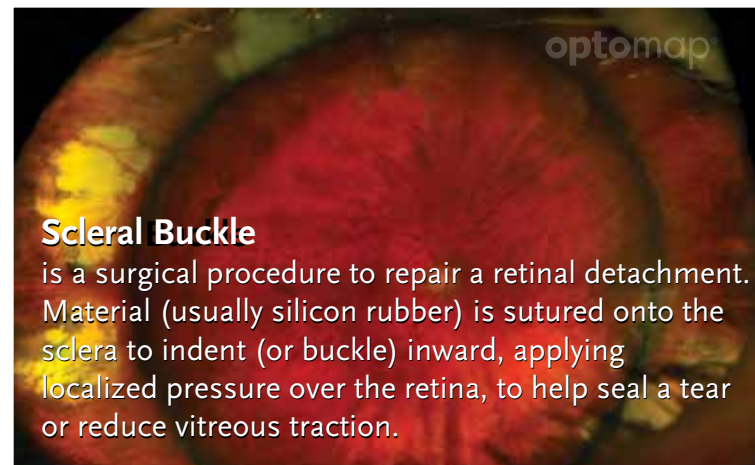
are particles that float in the vitreous and cast shadows on the retina; seen as spots, cobwebs, spiders, etc. Occurs normally with aging or with vitreous detachment, retinal tears or inflammation. Easily visible on **optomap** due to the SLO system which allows for clear visualization of pathology in the vitreous.



Treatment Options for a Retinal Detachment

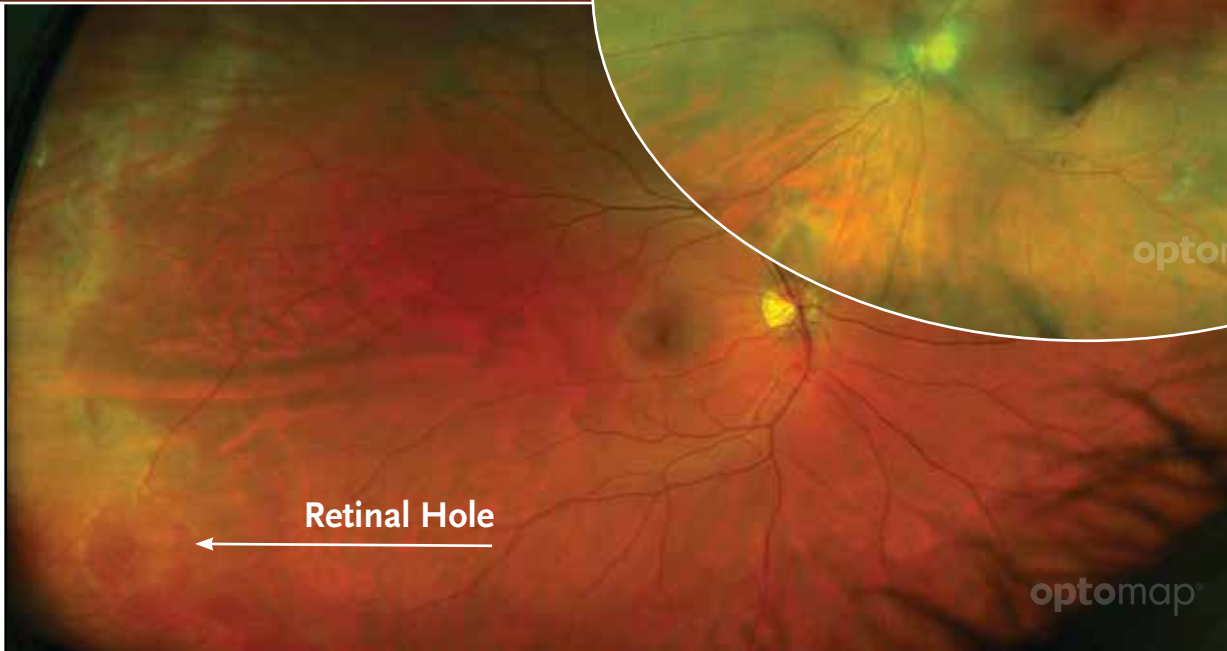
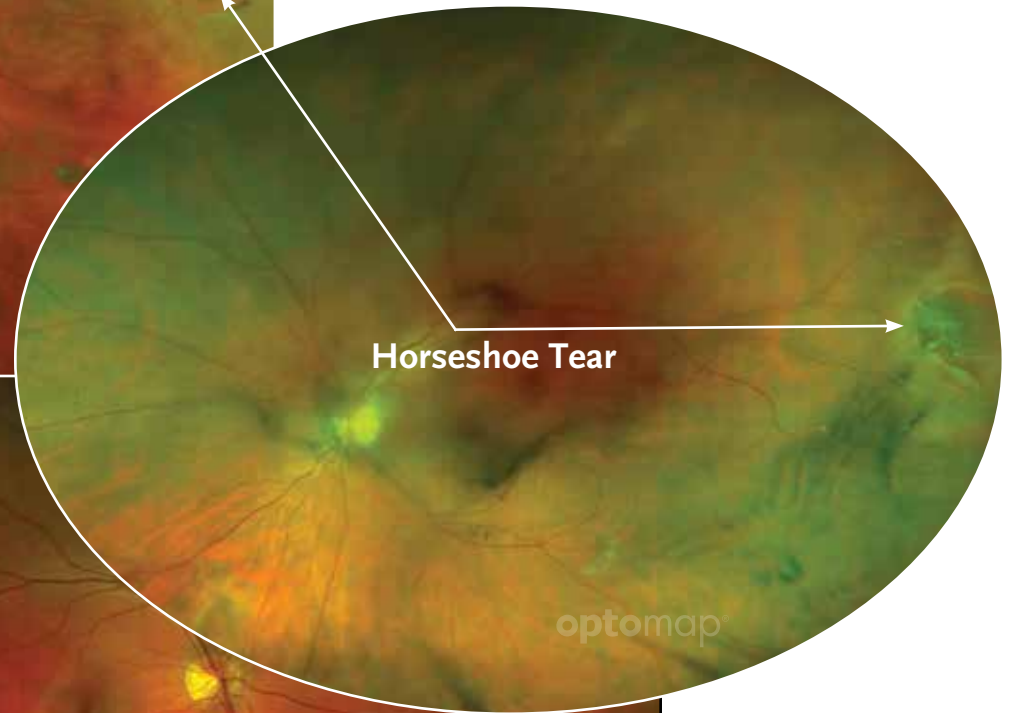
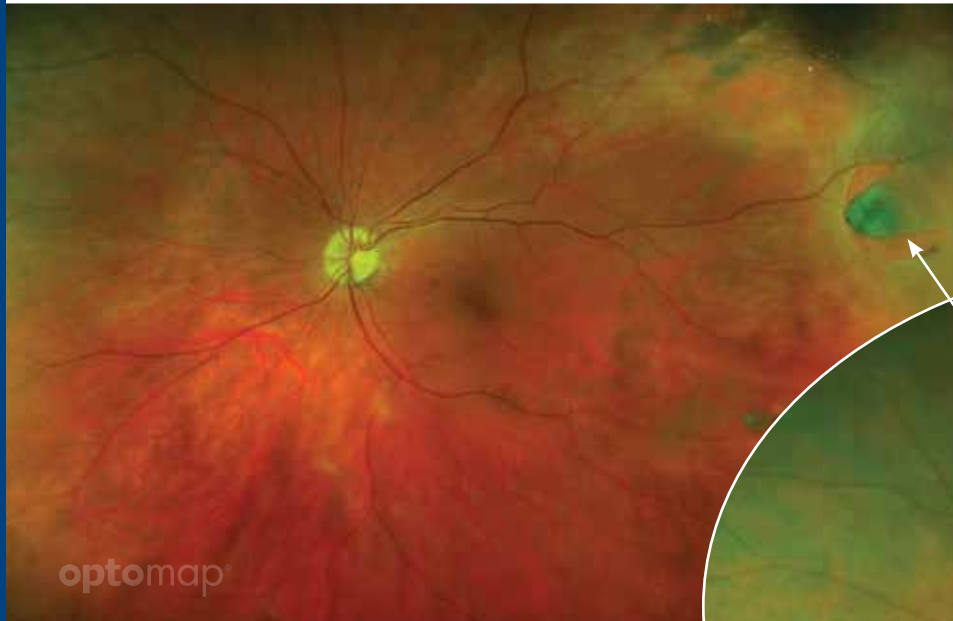


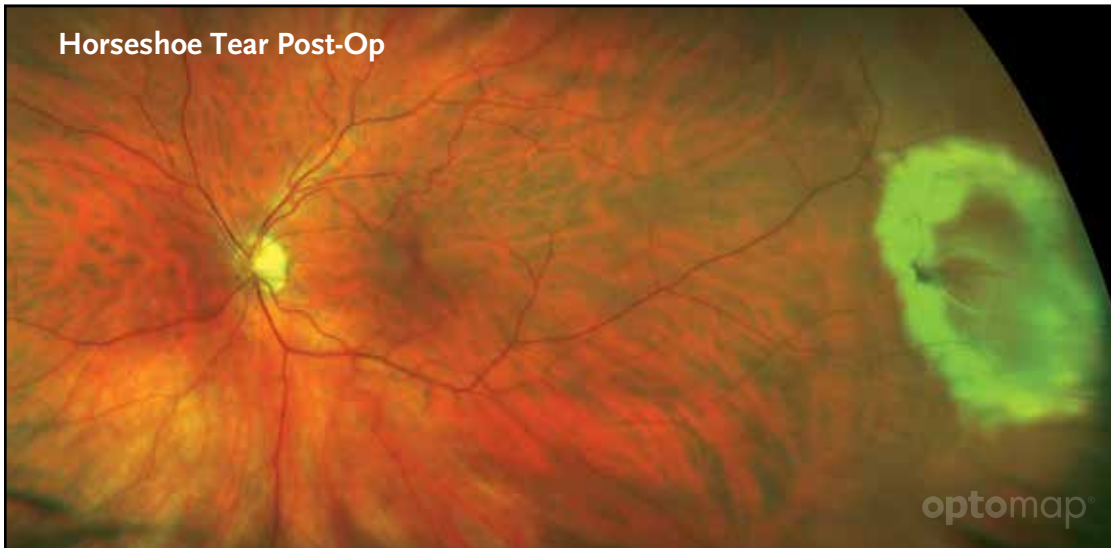
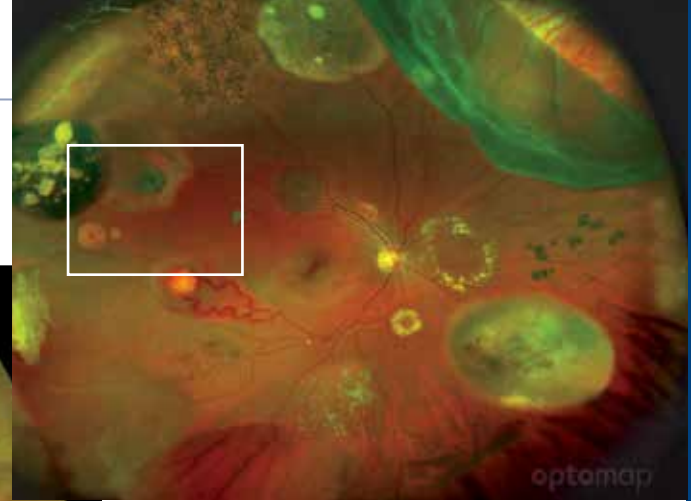
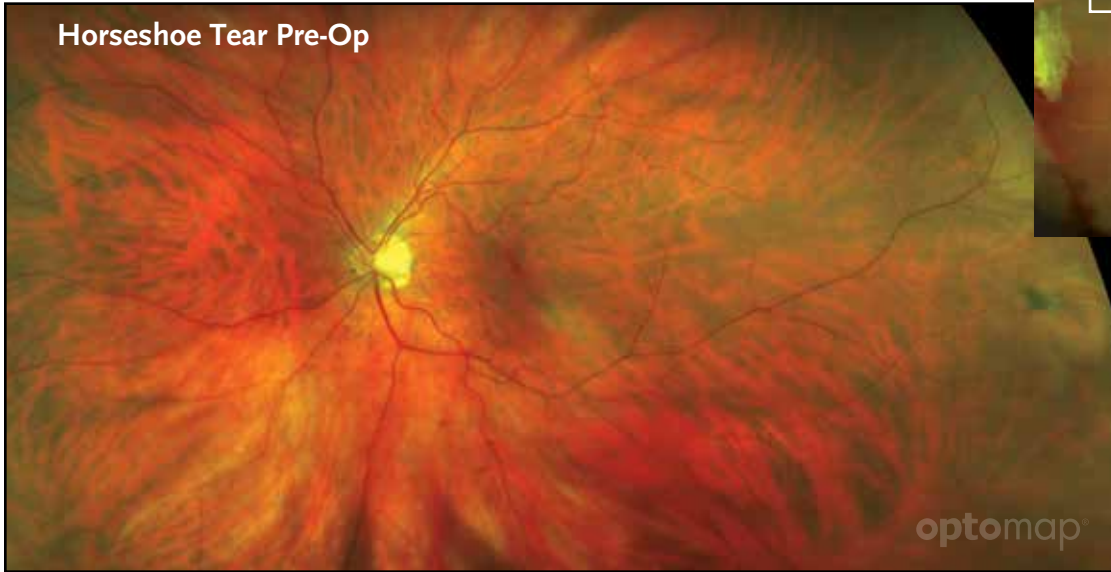3D wrap showing location of retinal detachment for patient education.





Retinal Holes and Tears

are small areas on the retina that are torn, if not treated they can lead to a retinal detachment. Small holes and tears are treated with laser surgery or a freeze treatment called *cryopexy*.









Optos has more than 20 years of ultra-widefield imaging experience with an extensive library of clinical studies. An ultra-widefield view of the retina helps eyecare professionals provide the best care for their patients.



Optos plc

Queensferry House
Carnegie Campus
Enterprise Way
Dunfermline, Fife
Scotland KY11 8GR
Tel: +44 (0)1383 843300
info@optos.com

Optos, Inc.

67 Forest Street
Marlborough, MA 01752
USA
Call Toll-free (US & Canada):
1-800-854-3039
Outside of the US: +1 508 787 1400
usinfo@optos.com

Optos Australia

10 Myer Court
Beverley
South Australia 5009
Tel: +61 8 8443 4533
auinfo@optos.com